

Anatomia hepática no transplante intervivos de figado

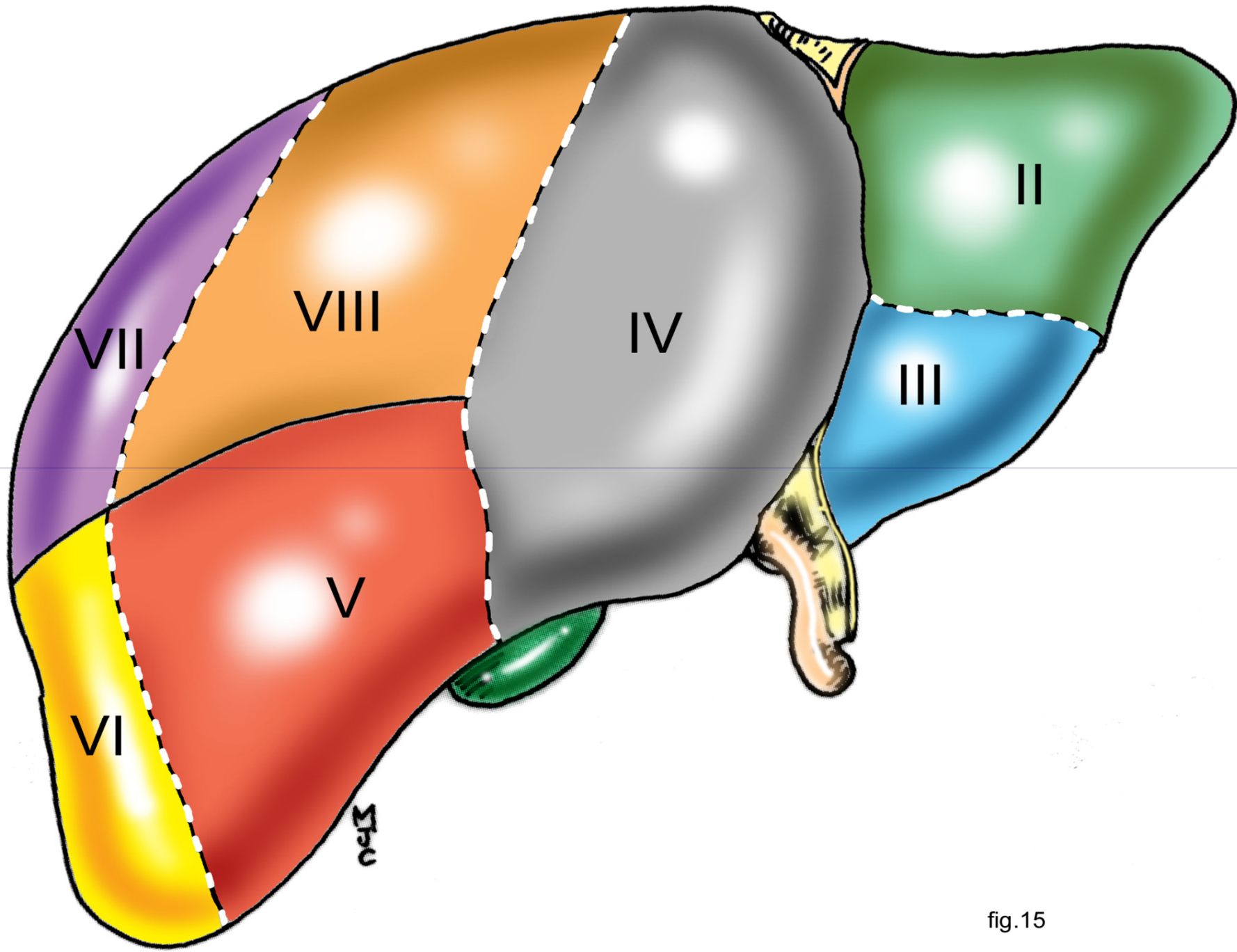
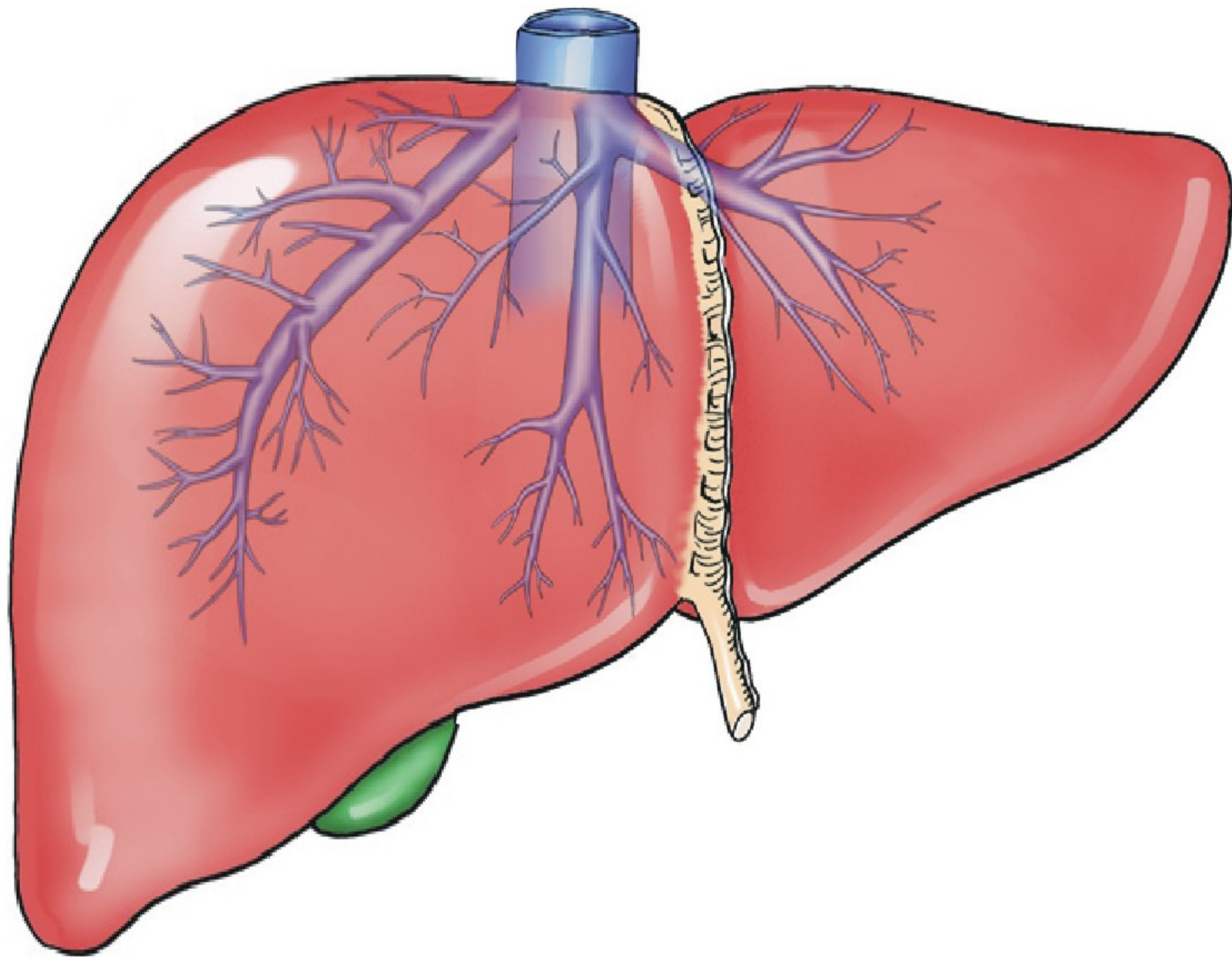


fig.15



Anatomia

- **Variações anatômicas**
- **Drenagem do setor medial do figado**
 predominio da VHM
 predominio da VHD

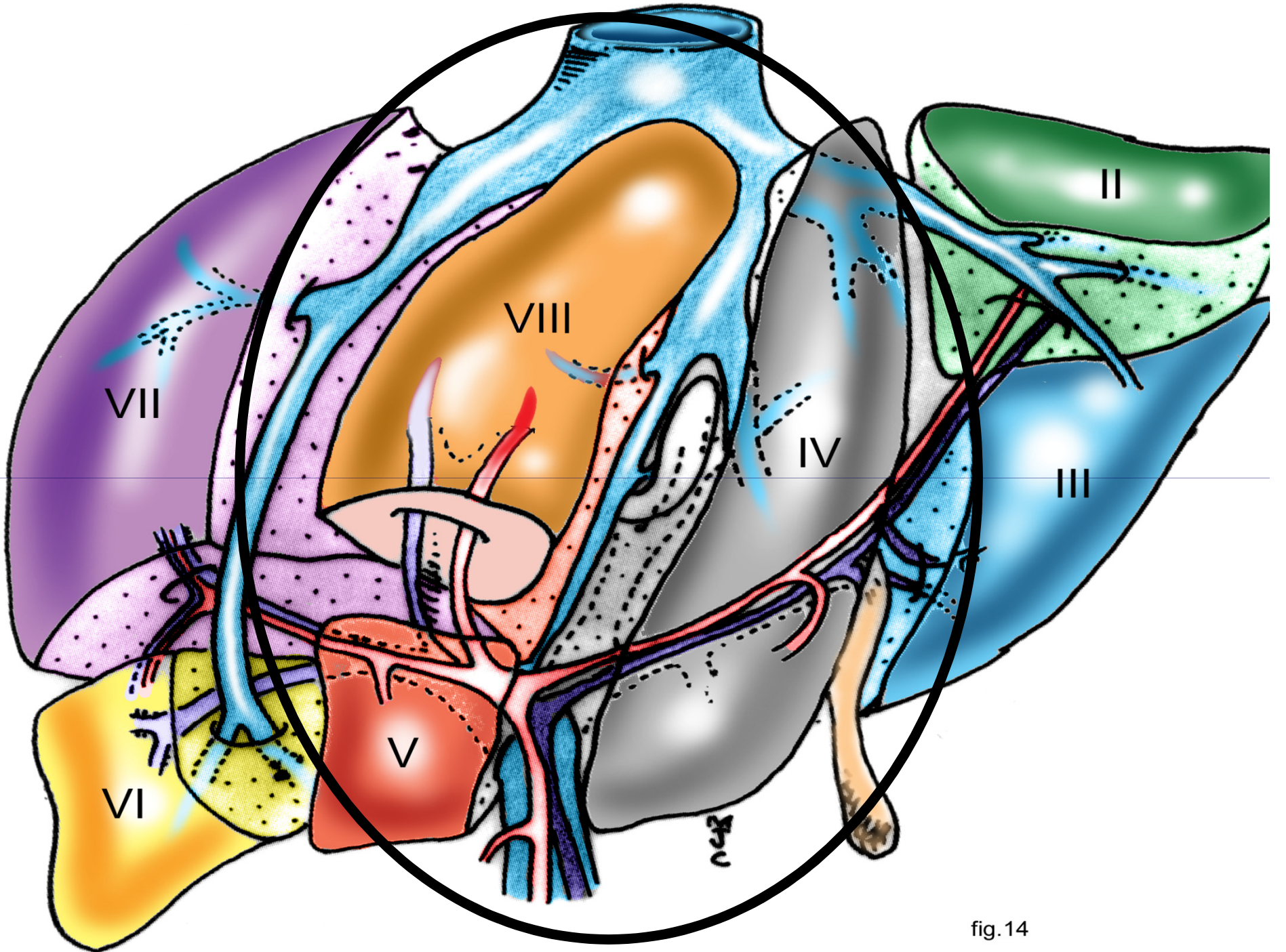
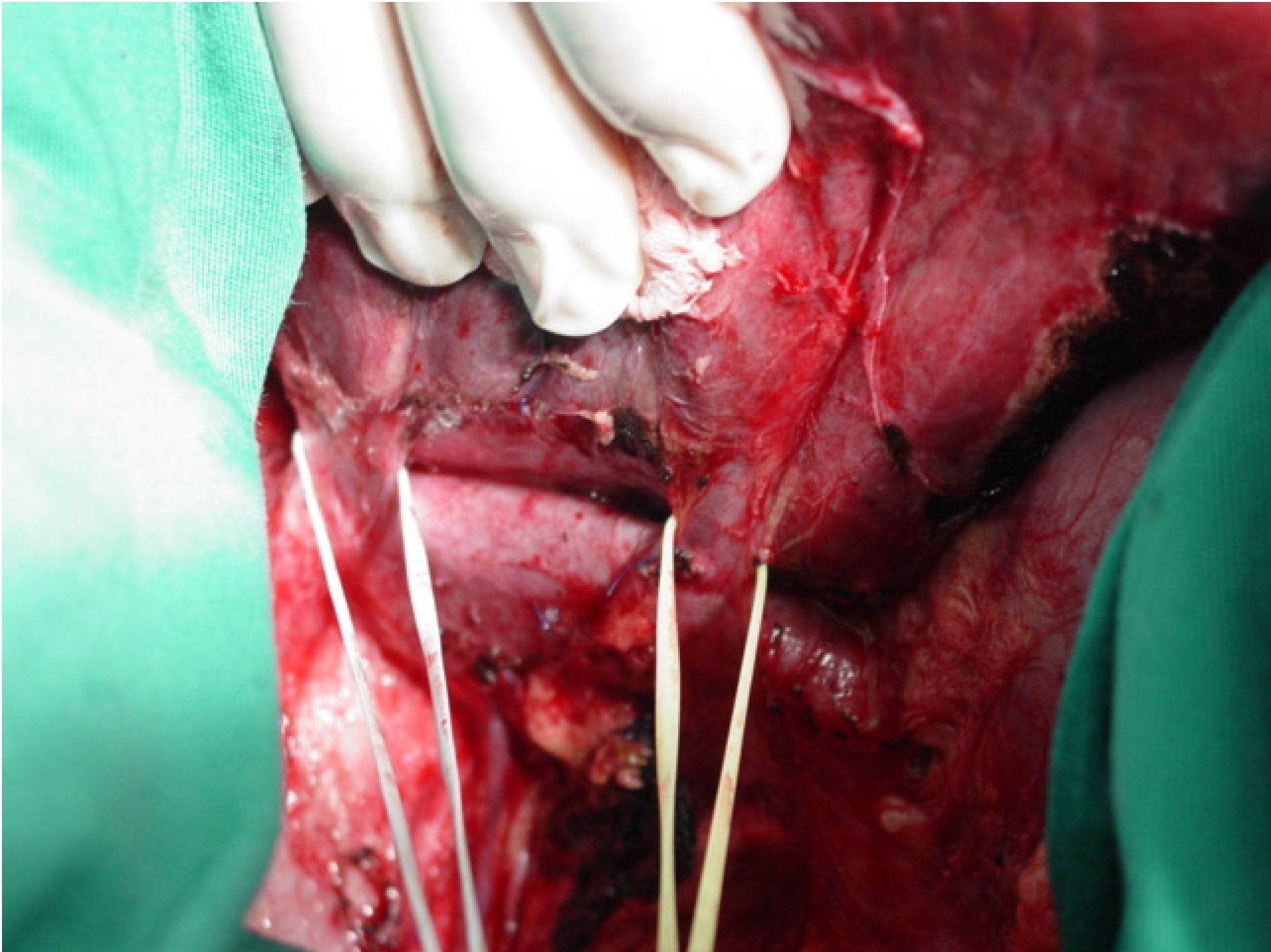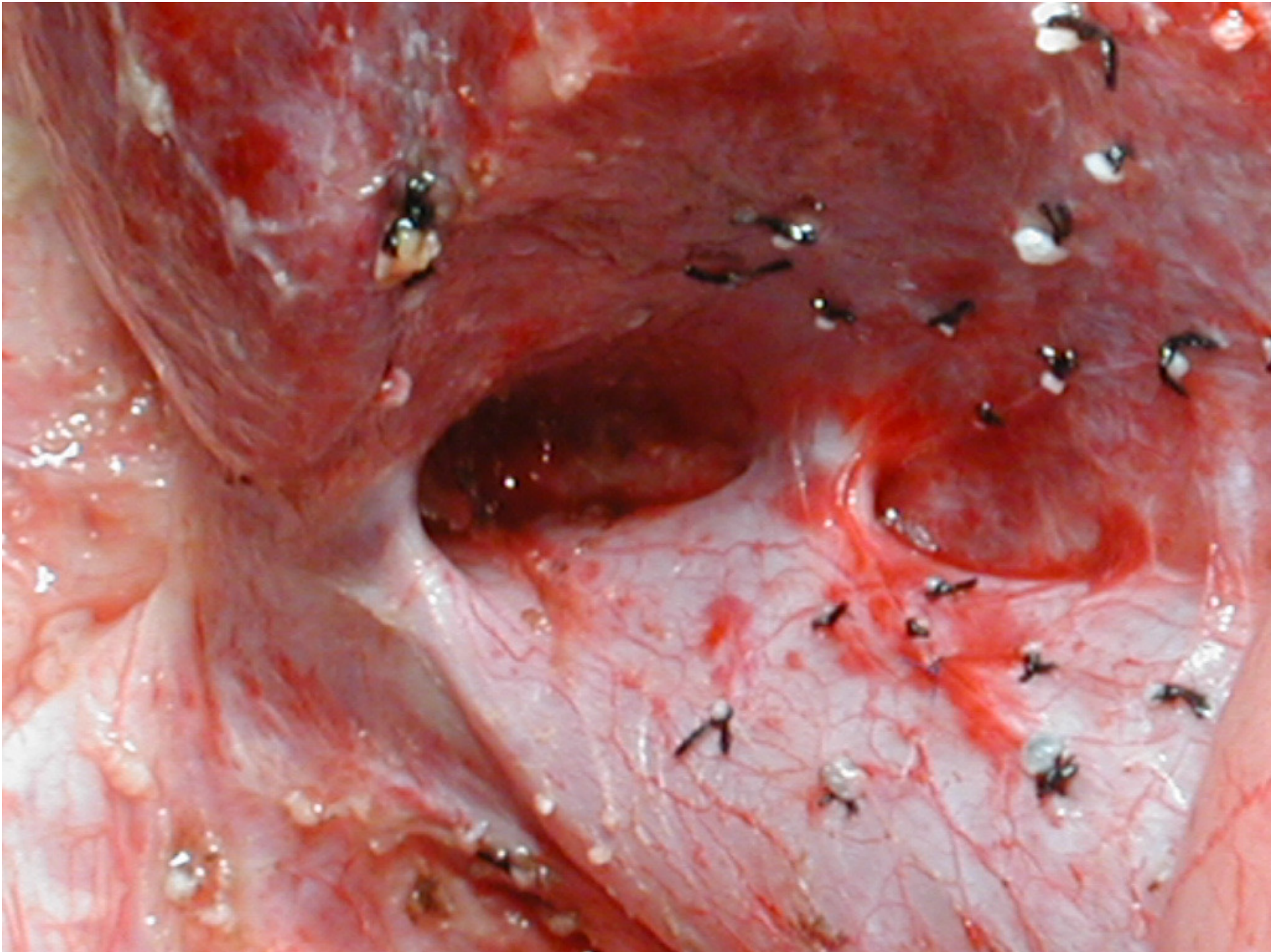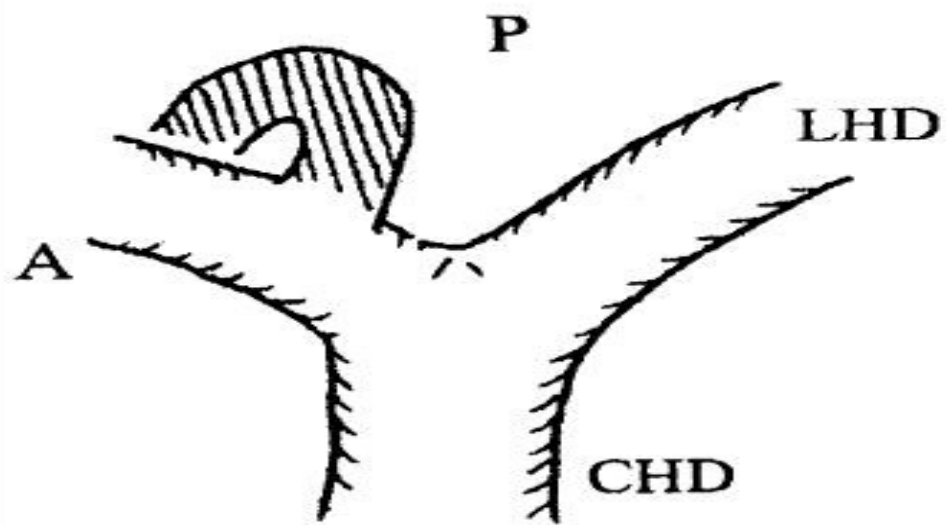


fig.14

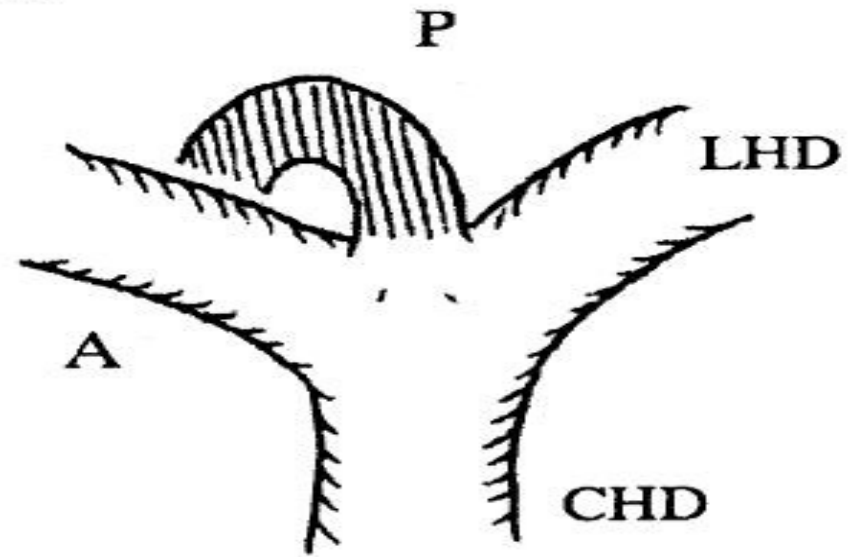




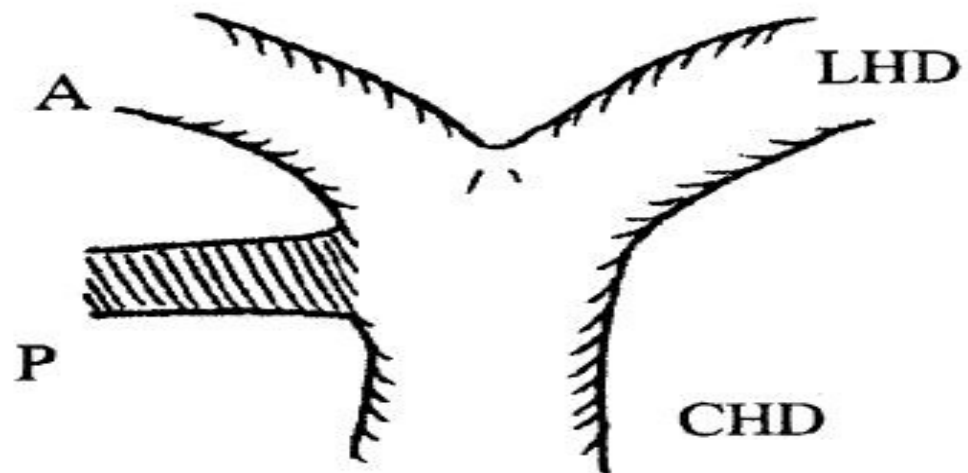
Type I



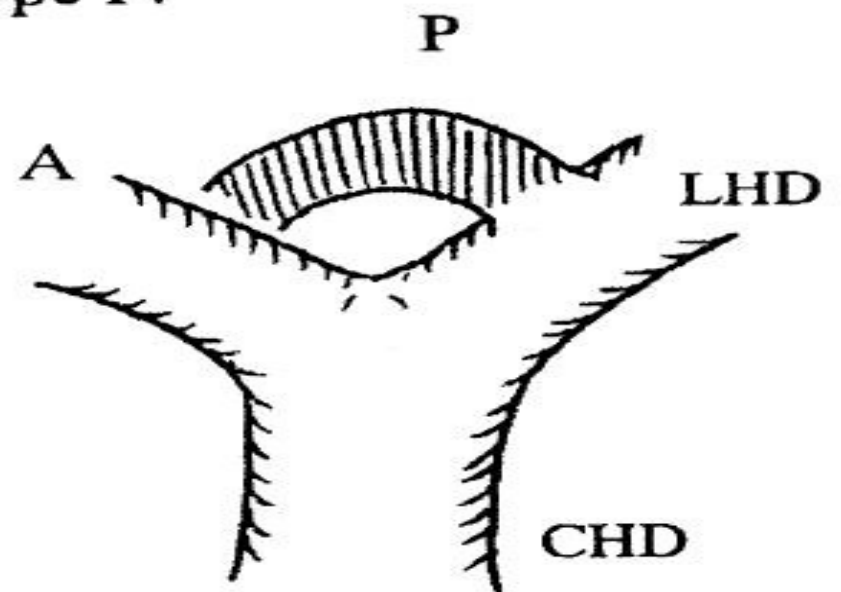
Type II

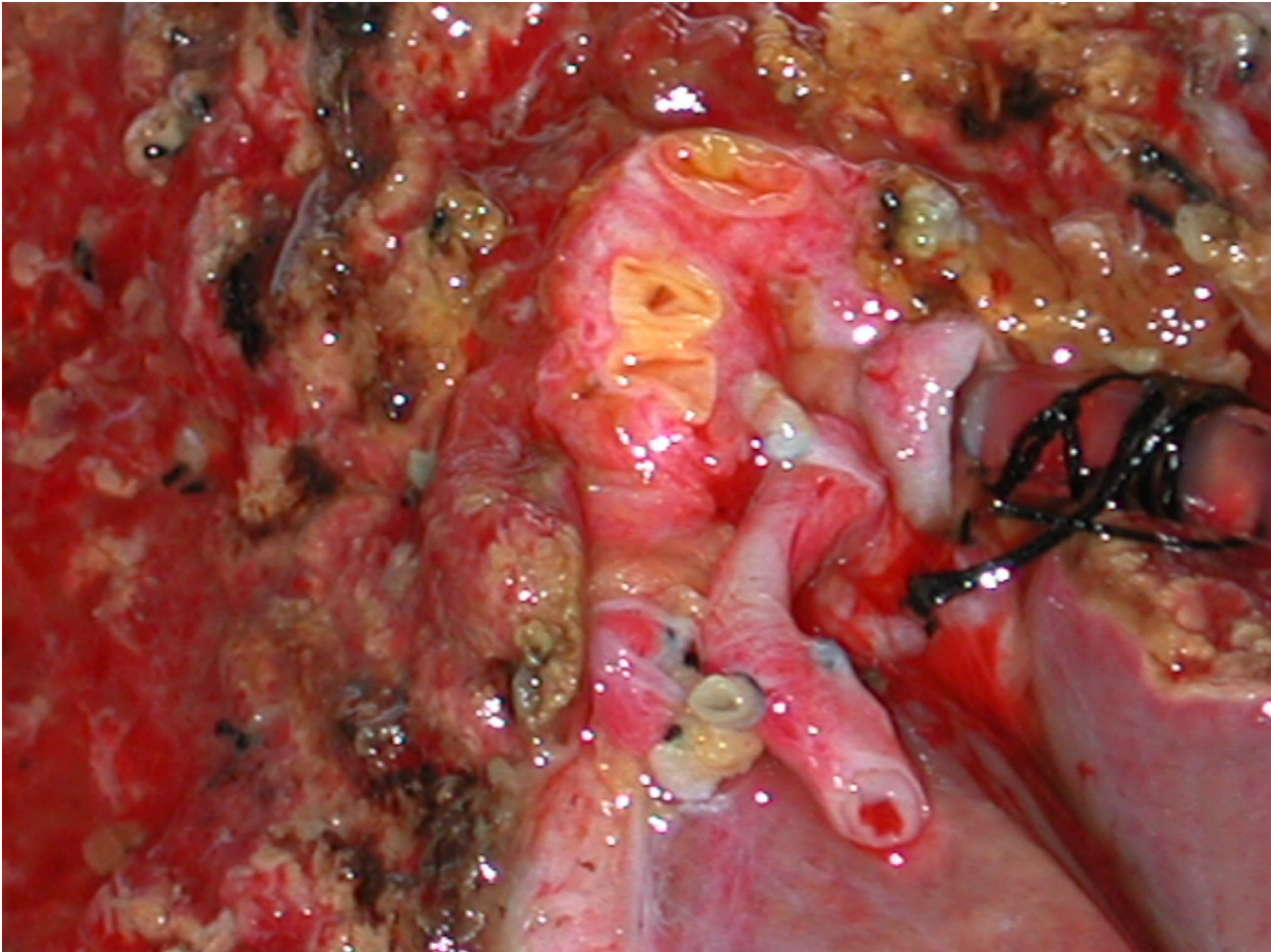


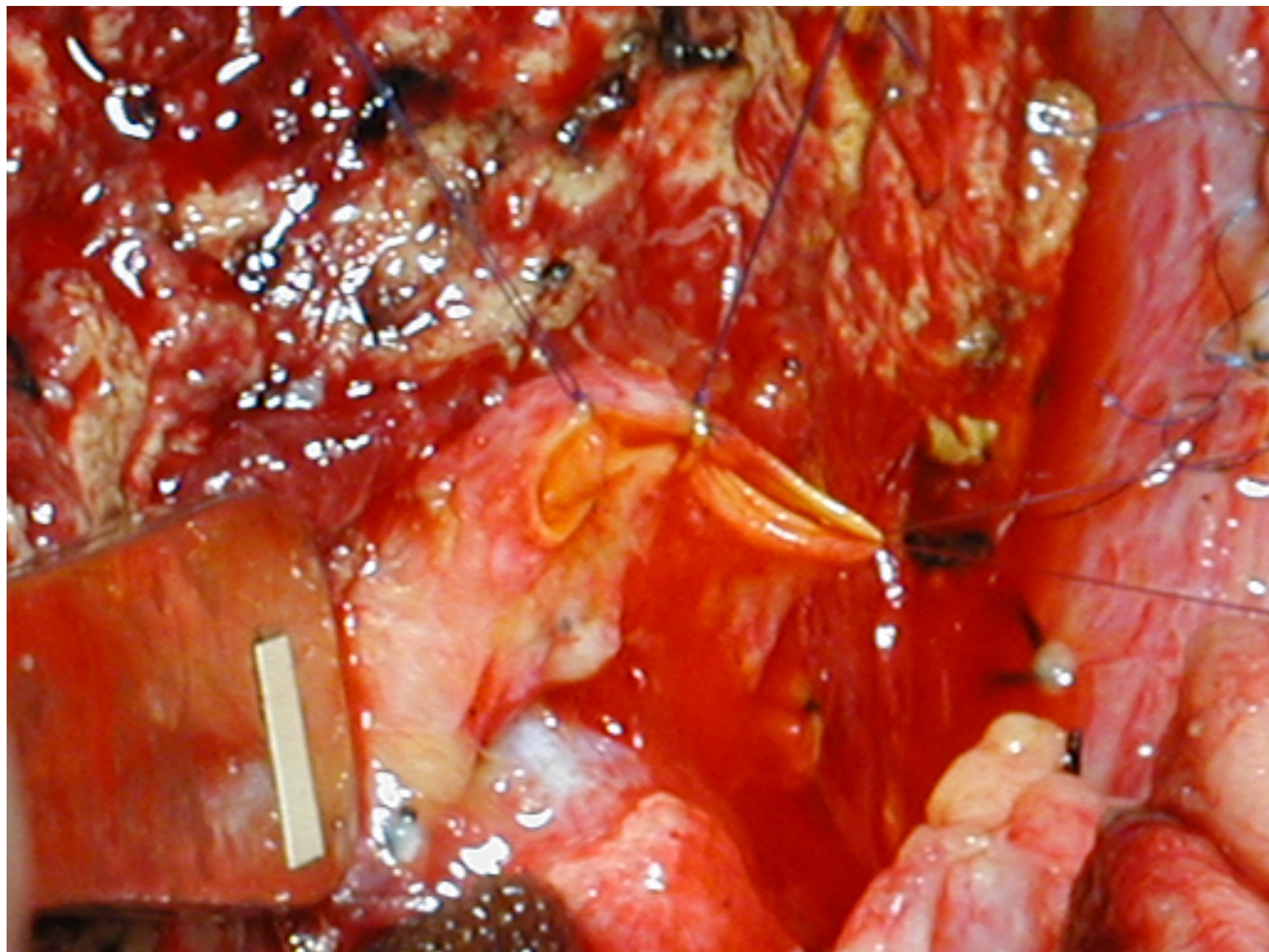
Type III

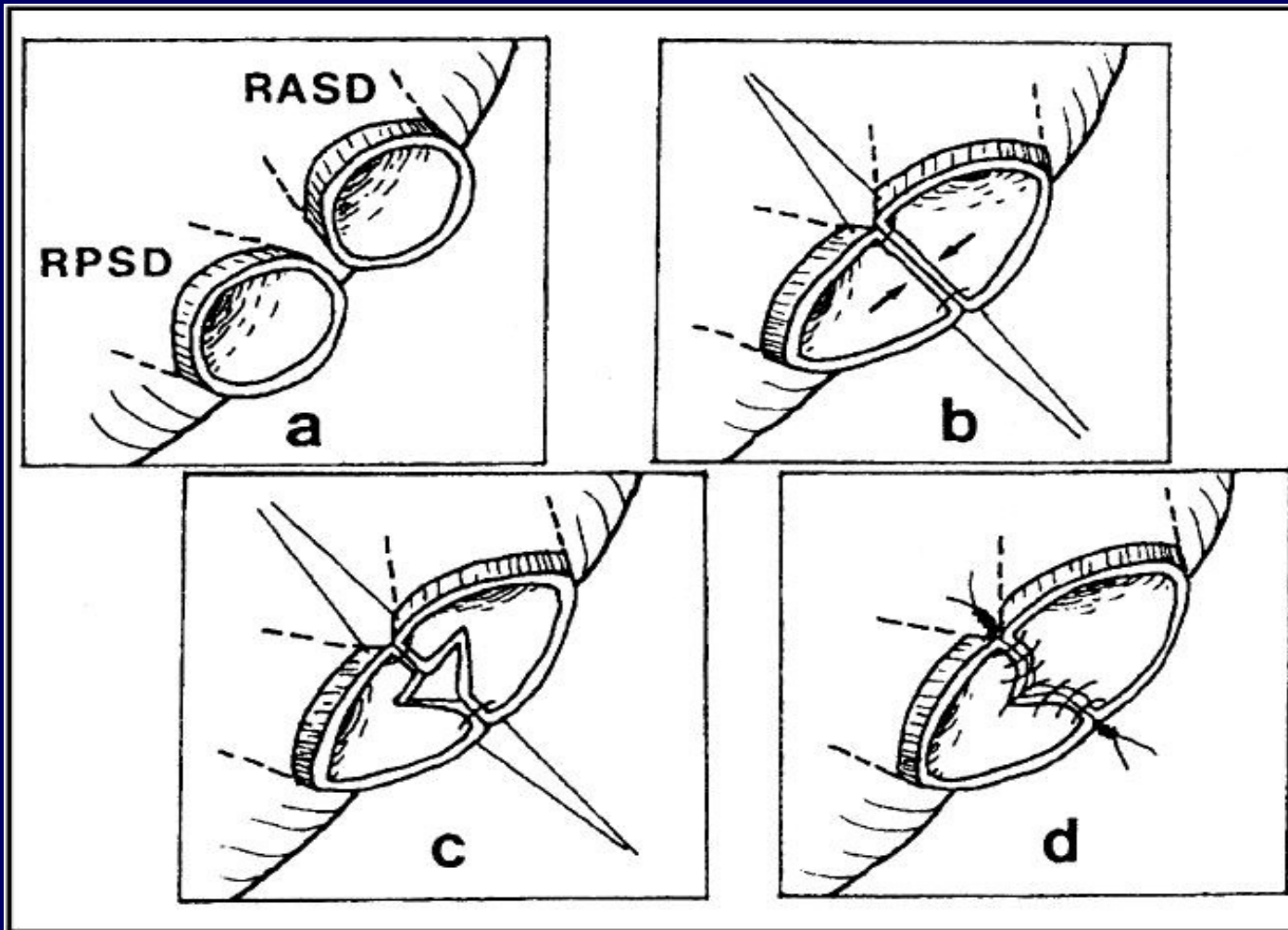


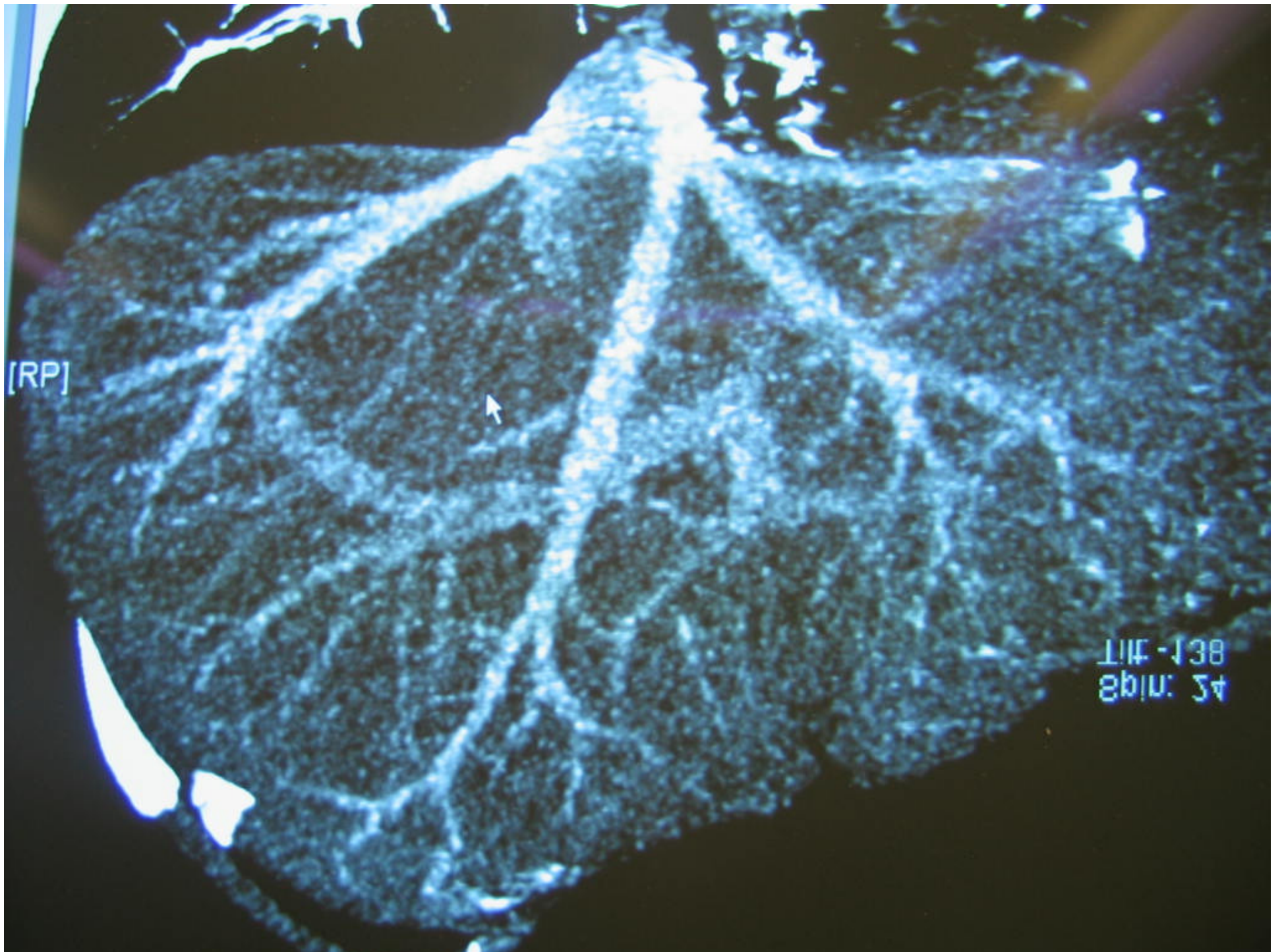
Type IV

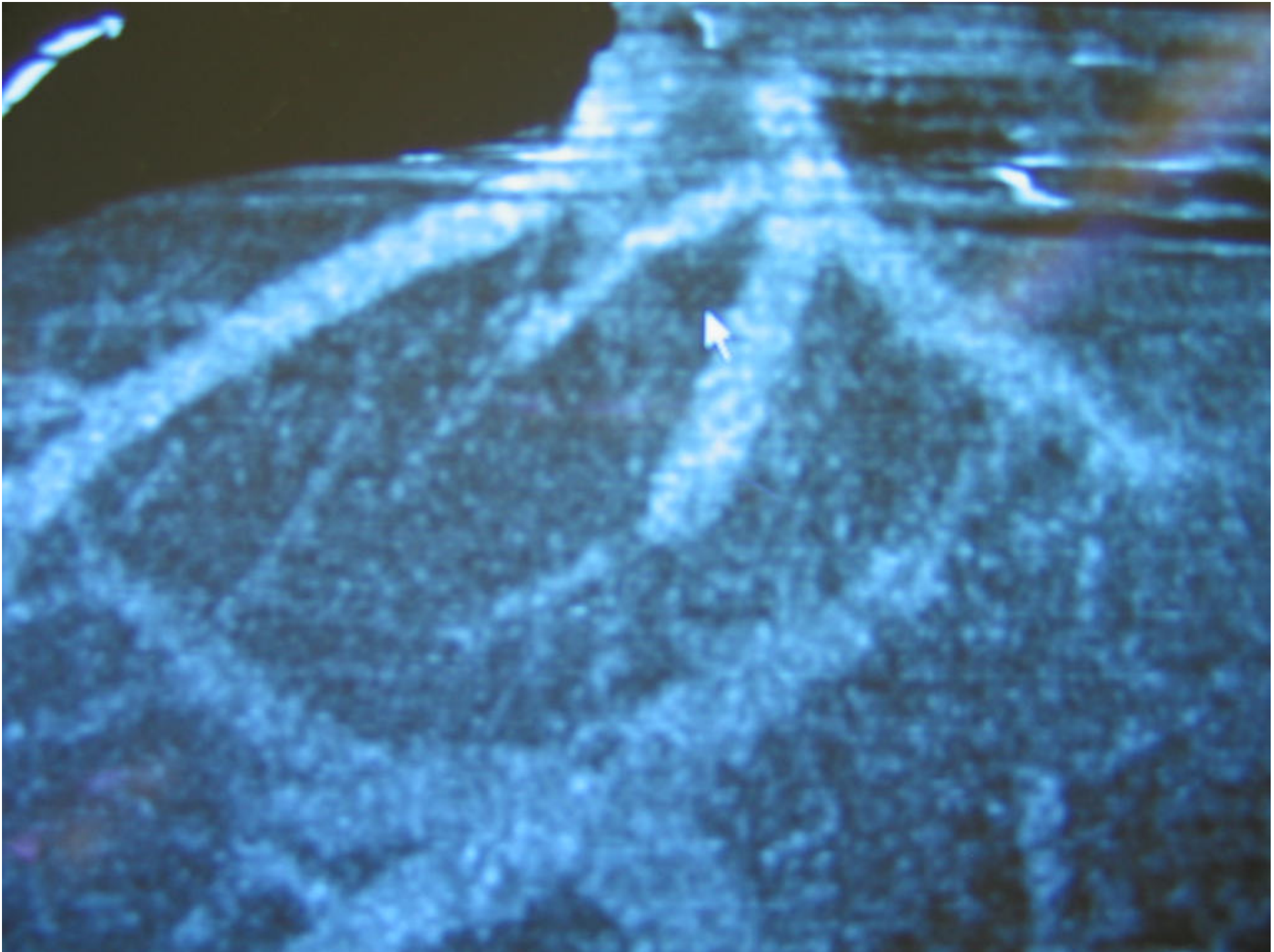


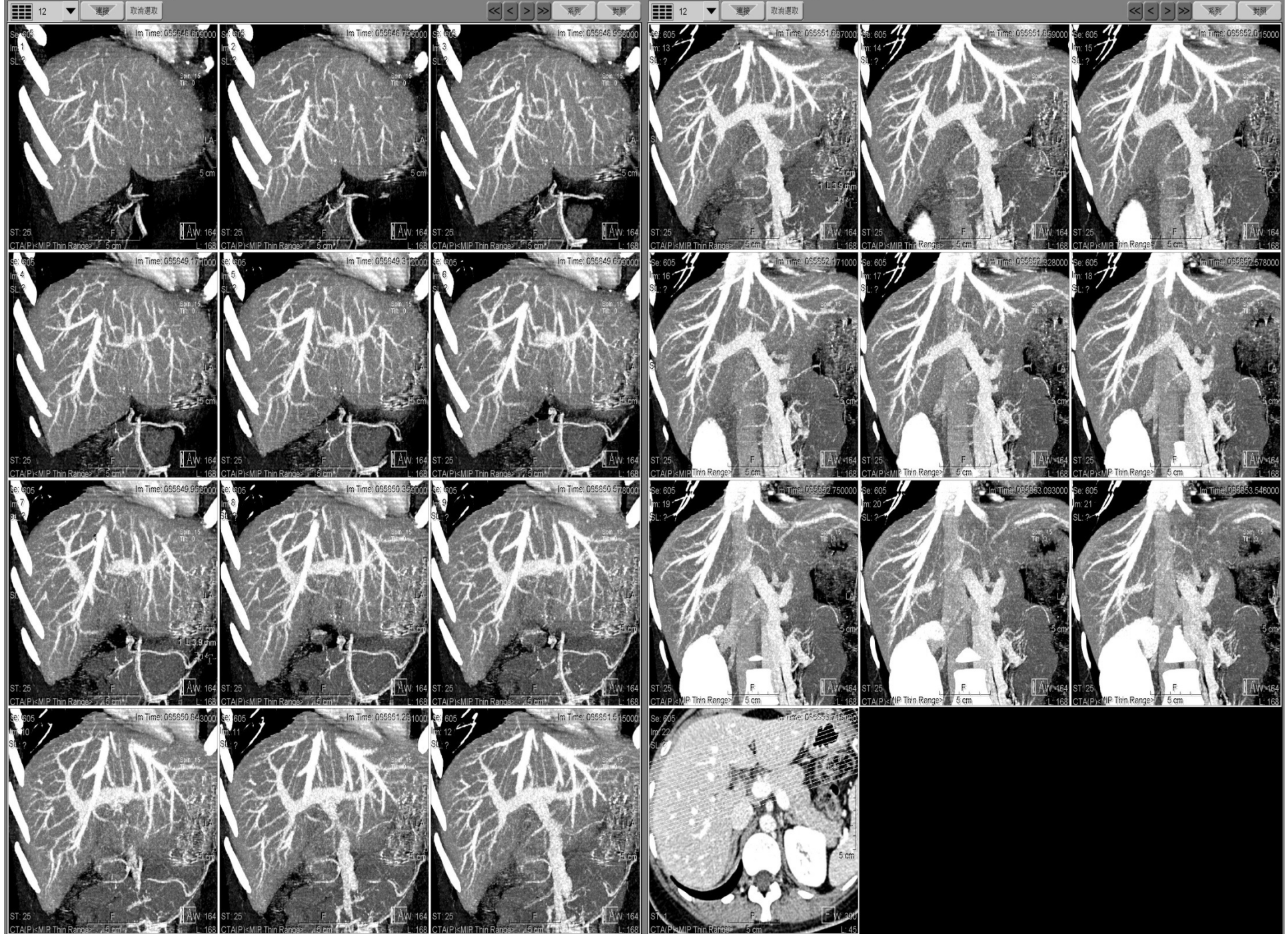










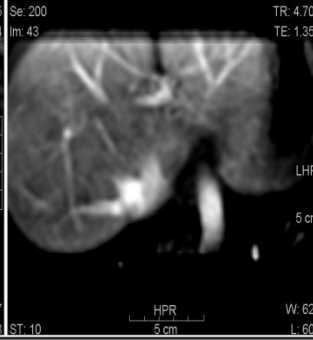
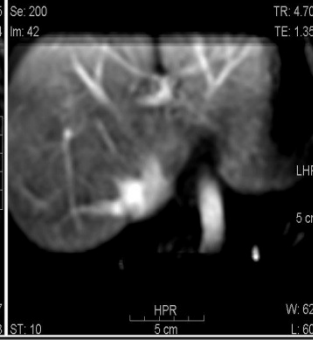
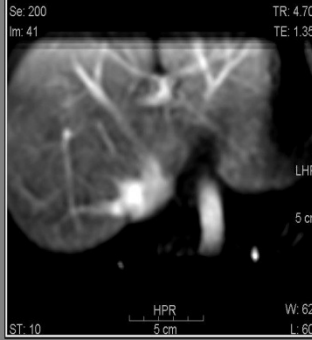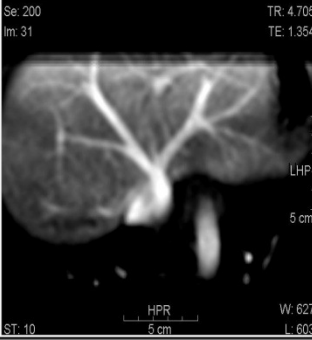
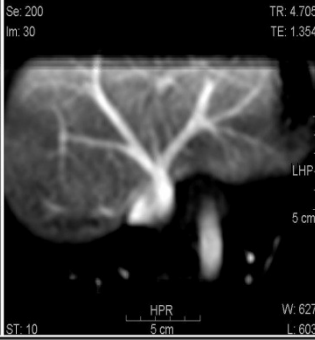
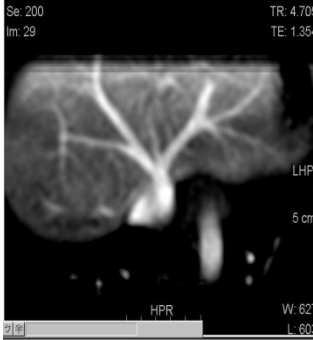
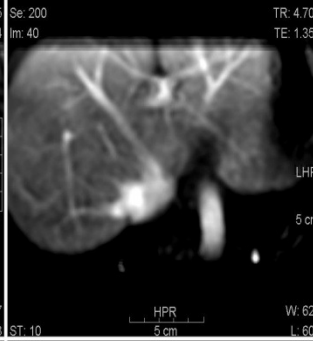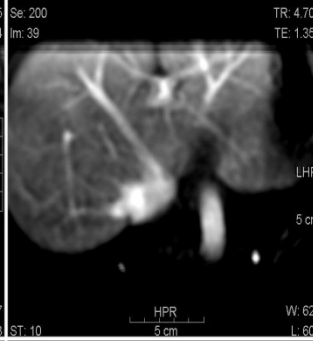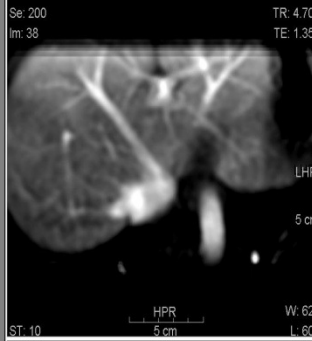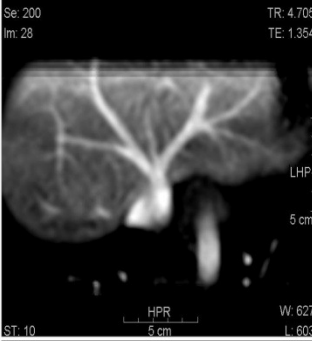
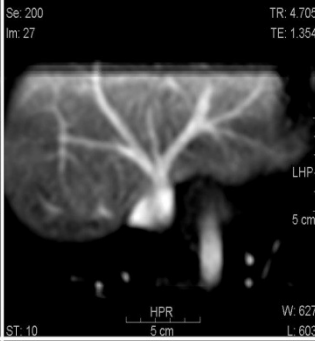
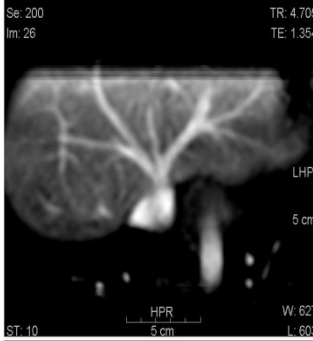
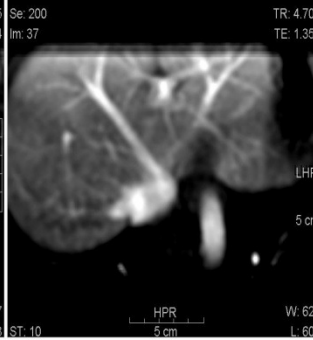
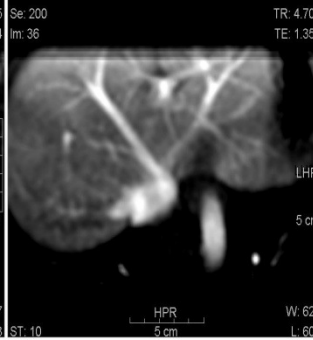
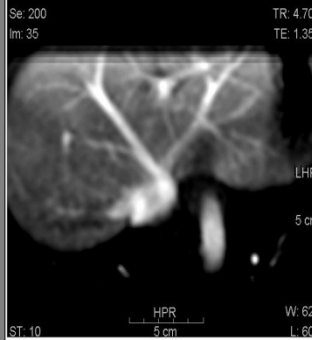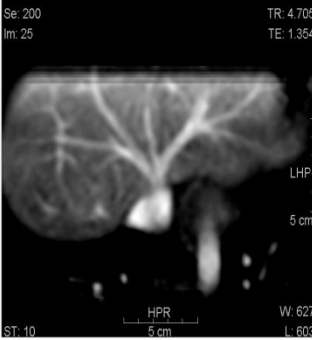
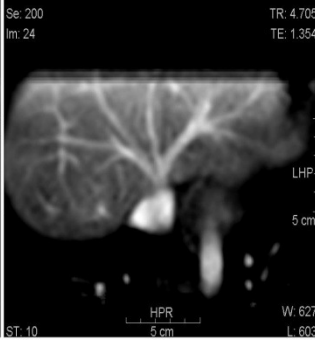
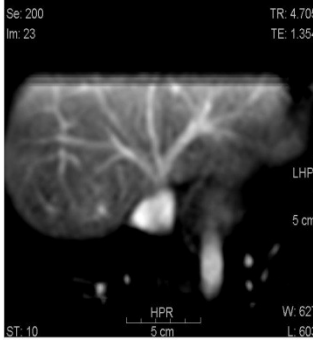
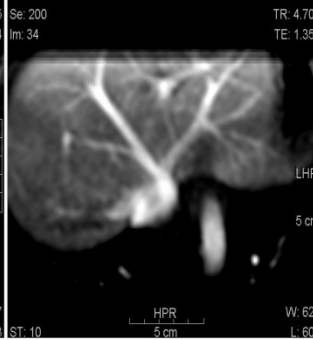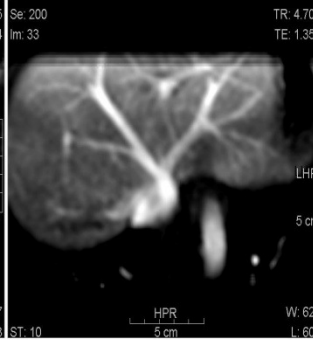
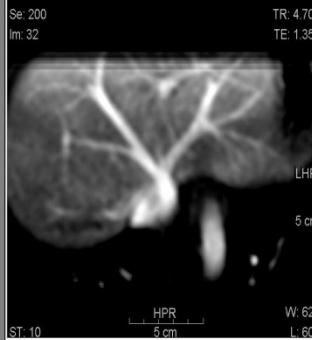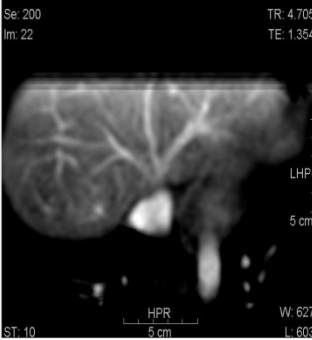
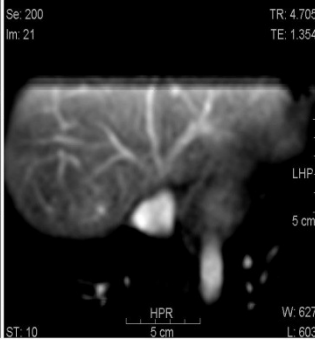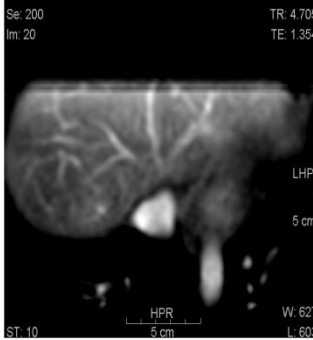


12 選擇 取消選擇

系列 對照

12 選擇 取消選擇

系列 對照





12

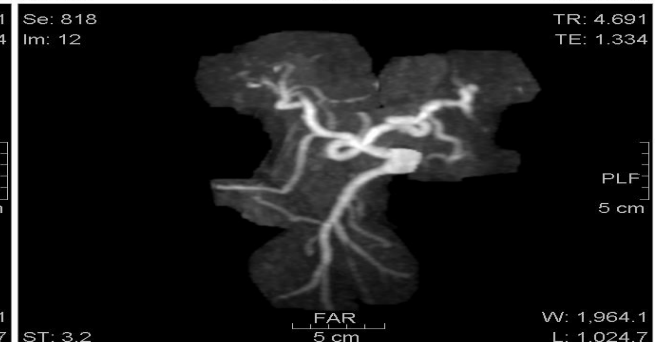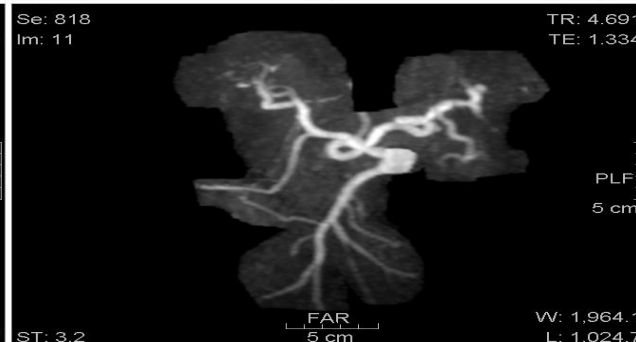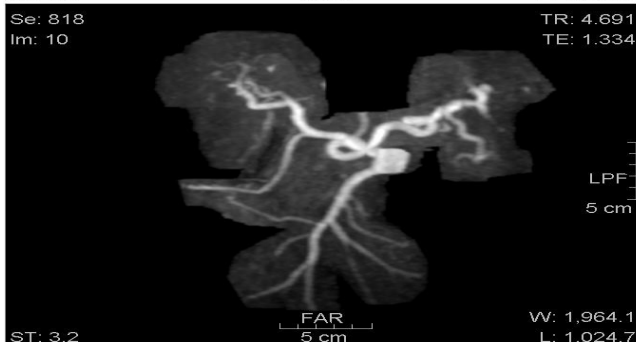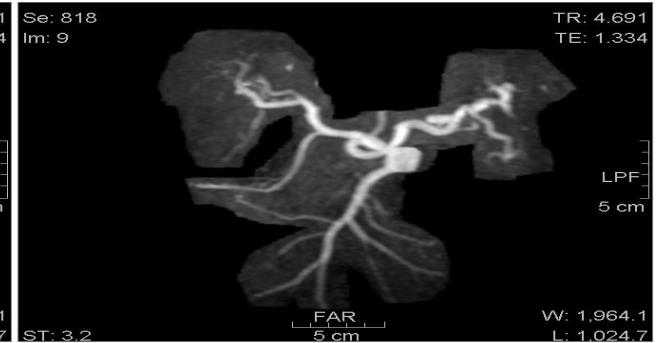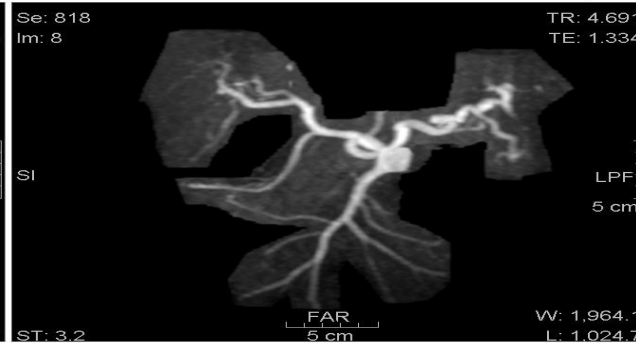
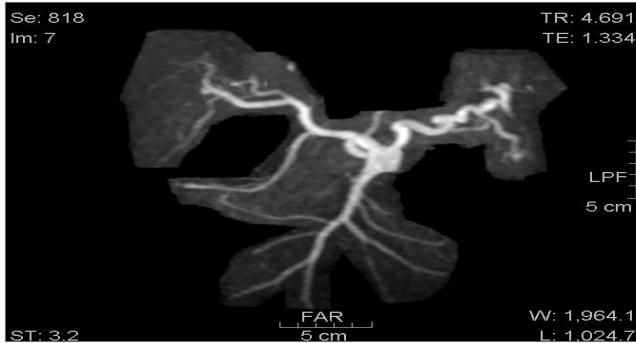
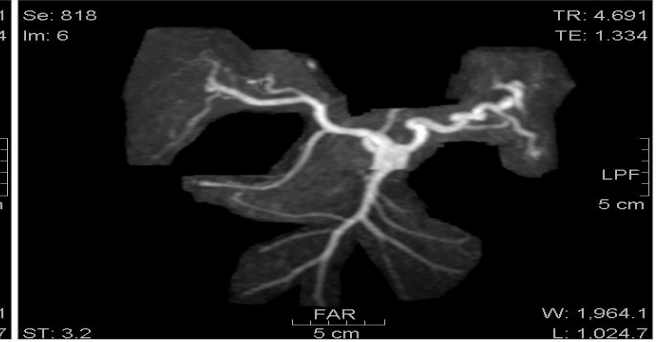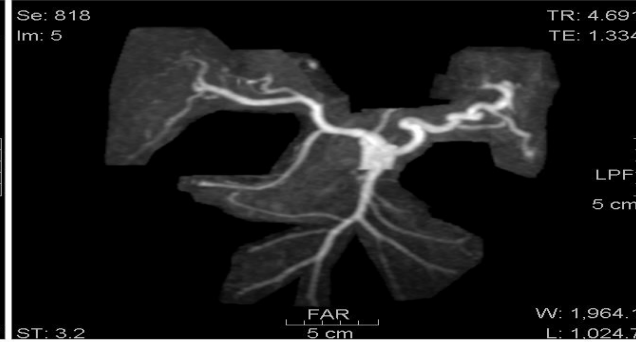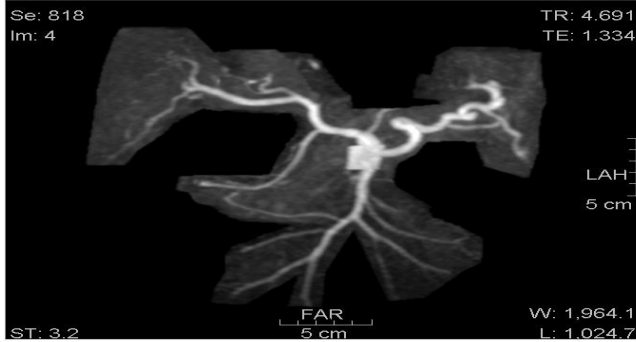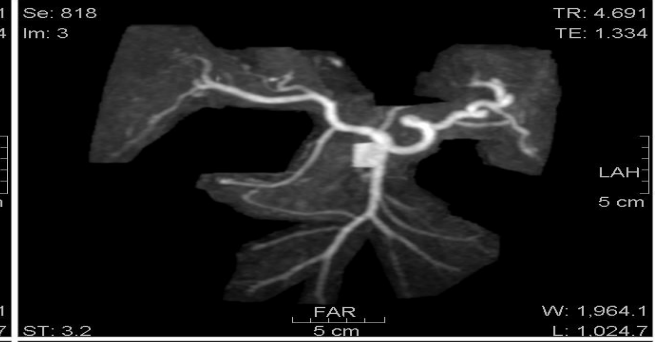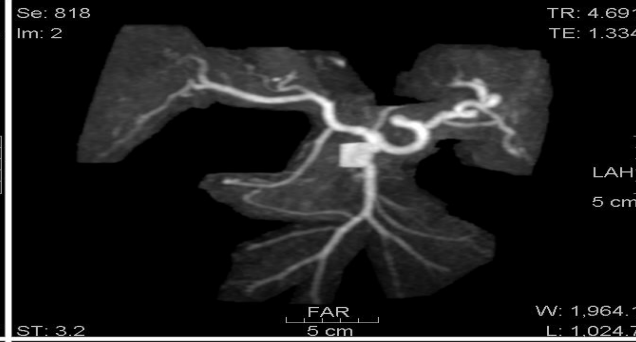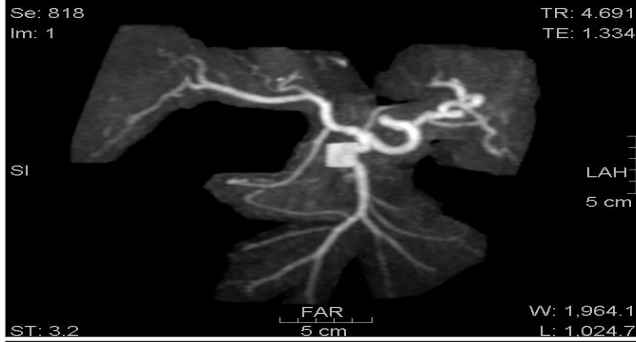連接

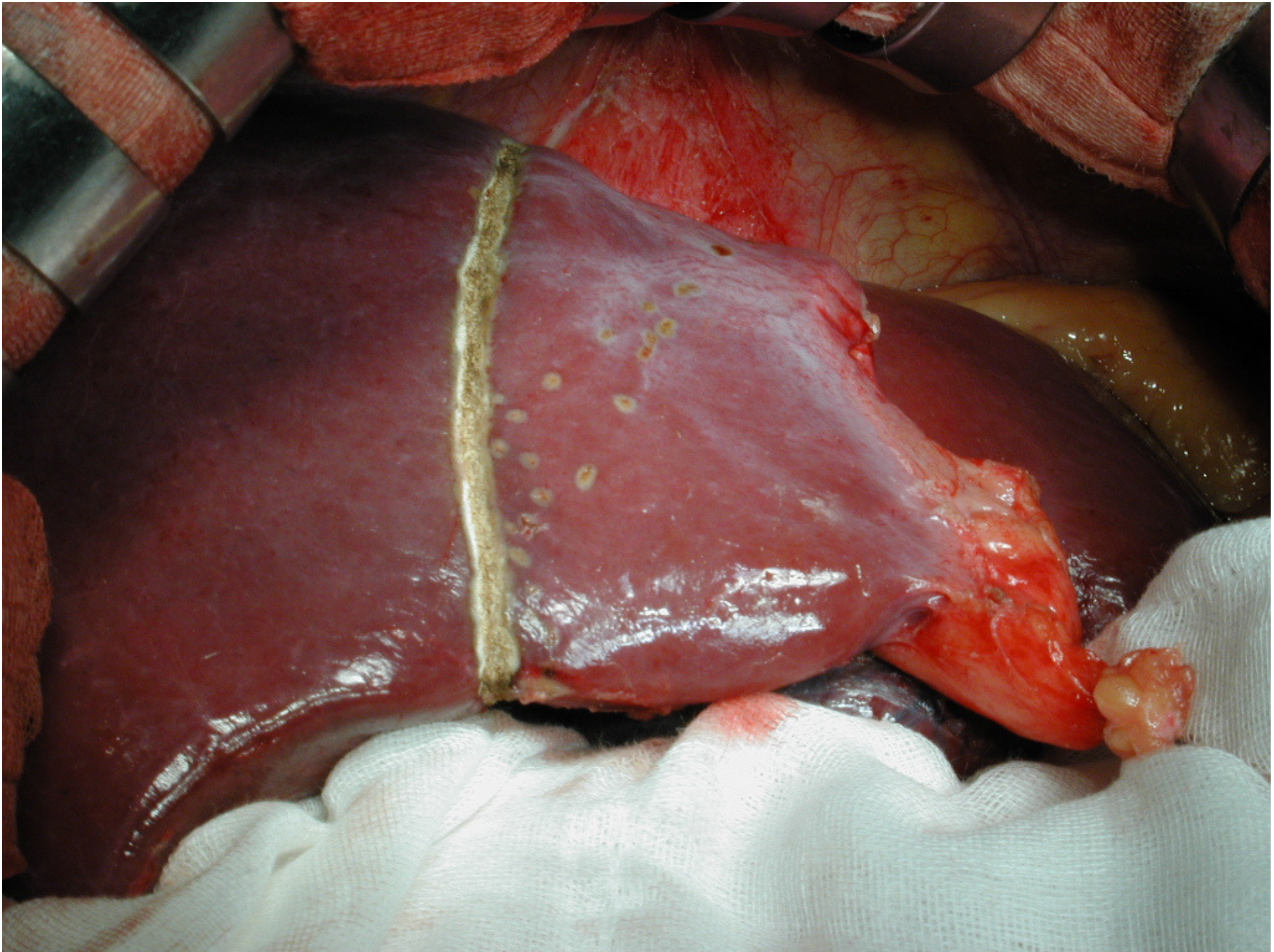
取消選取

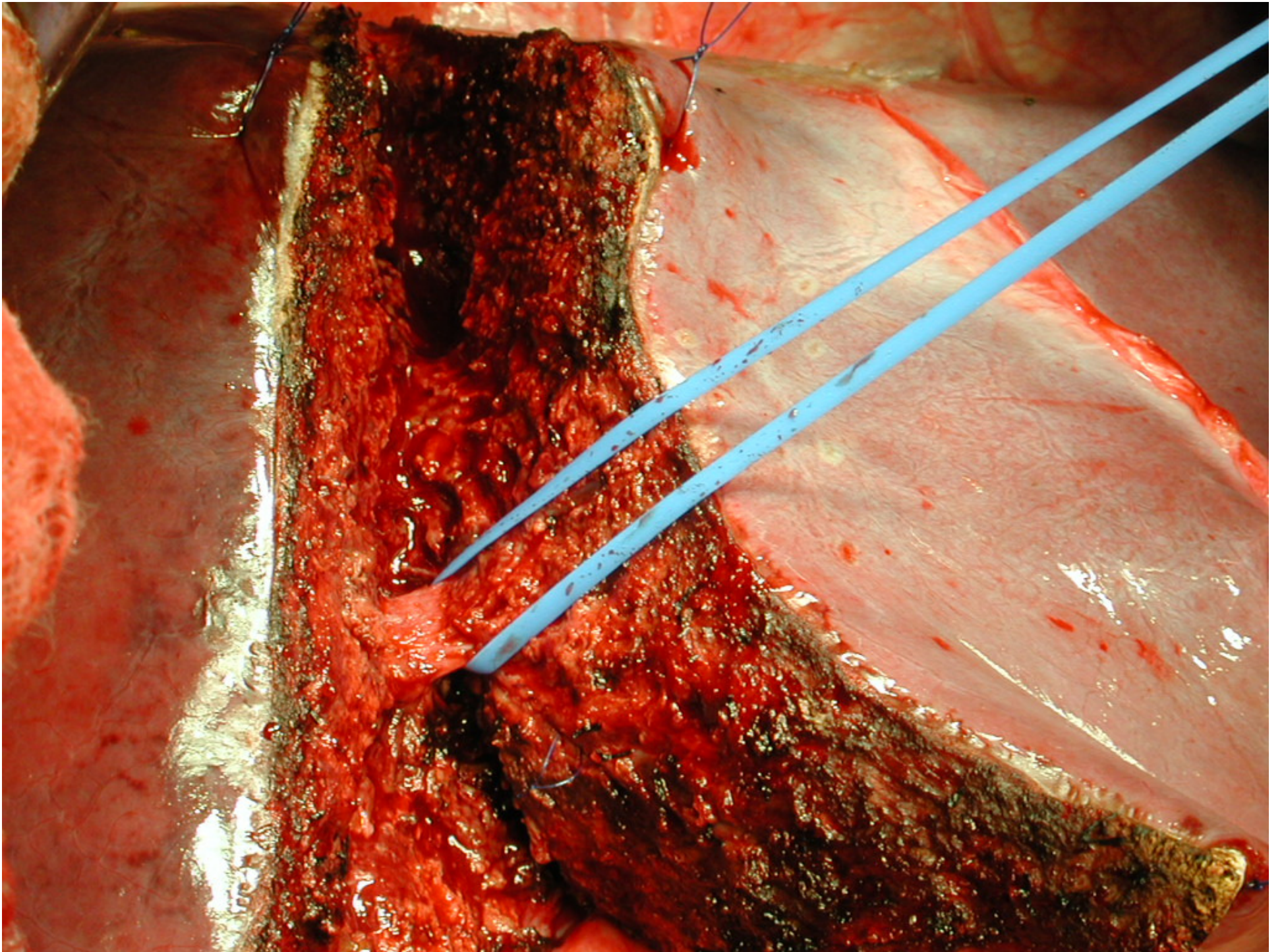


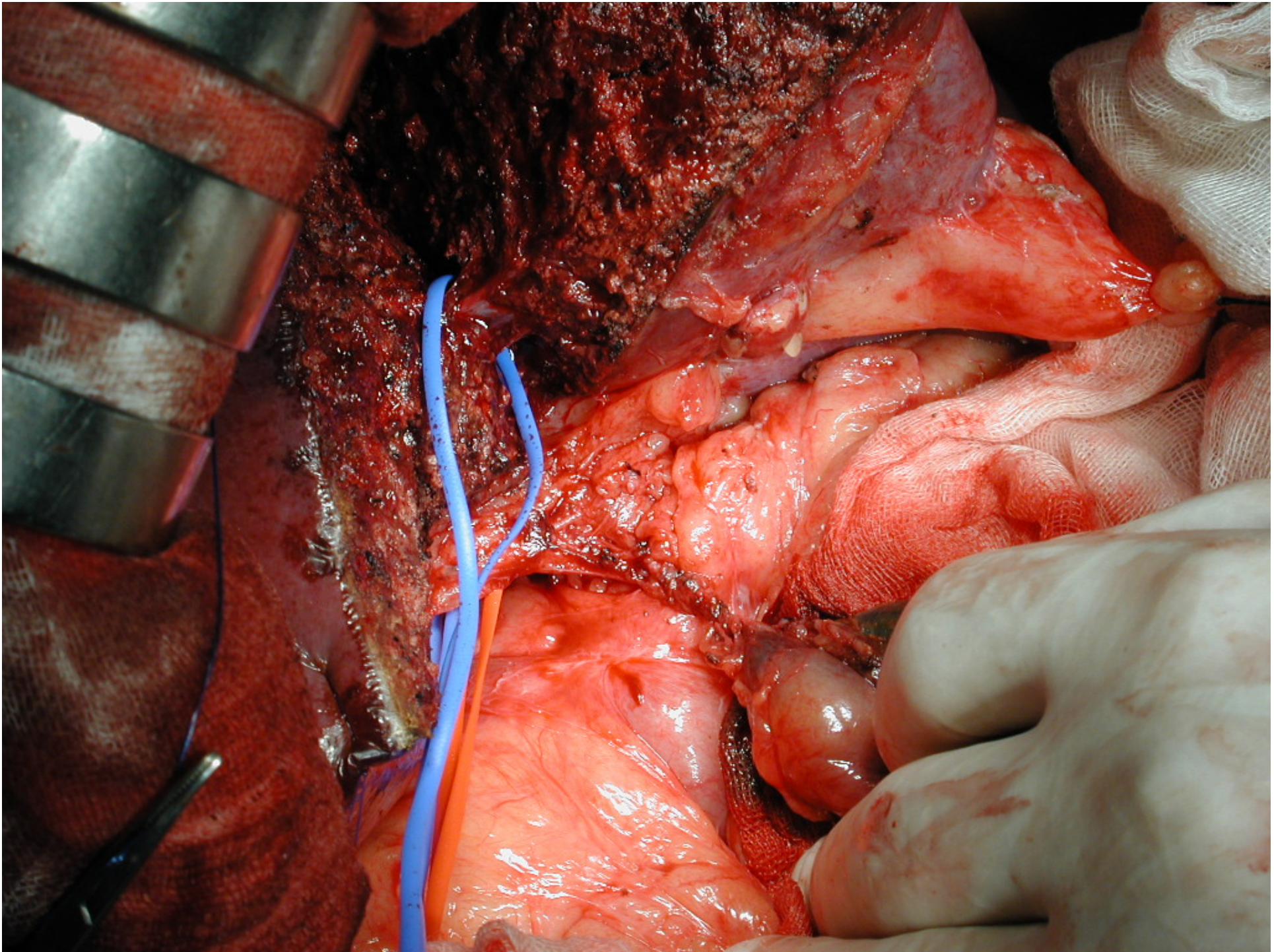
系列

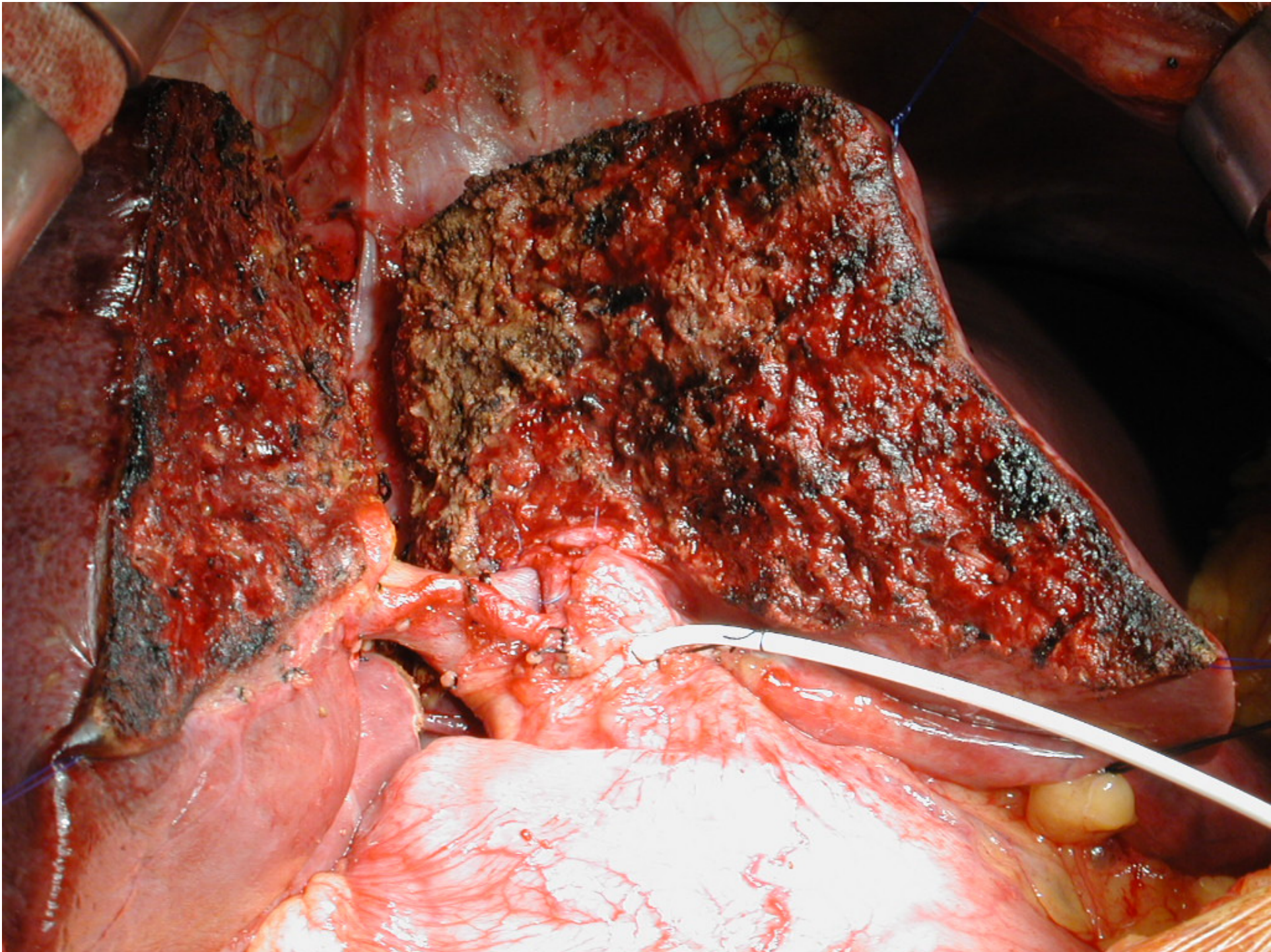
對照



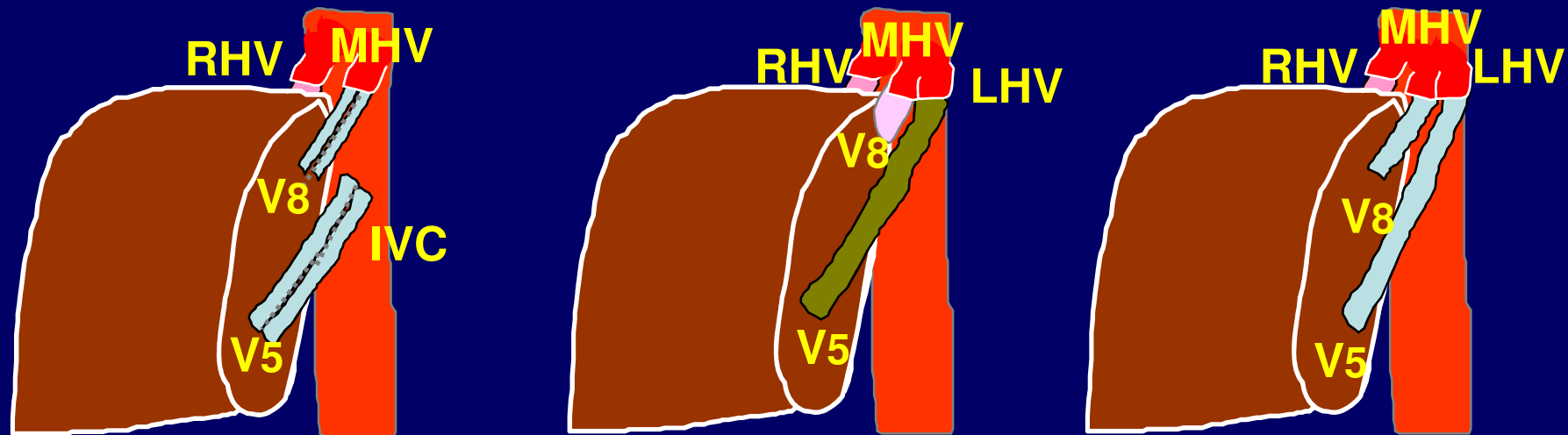




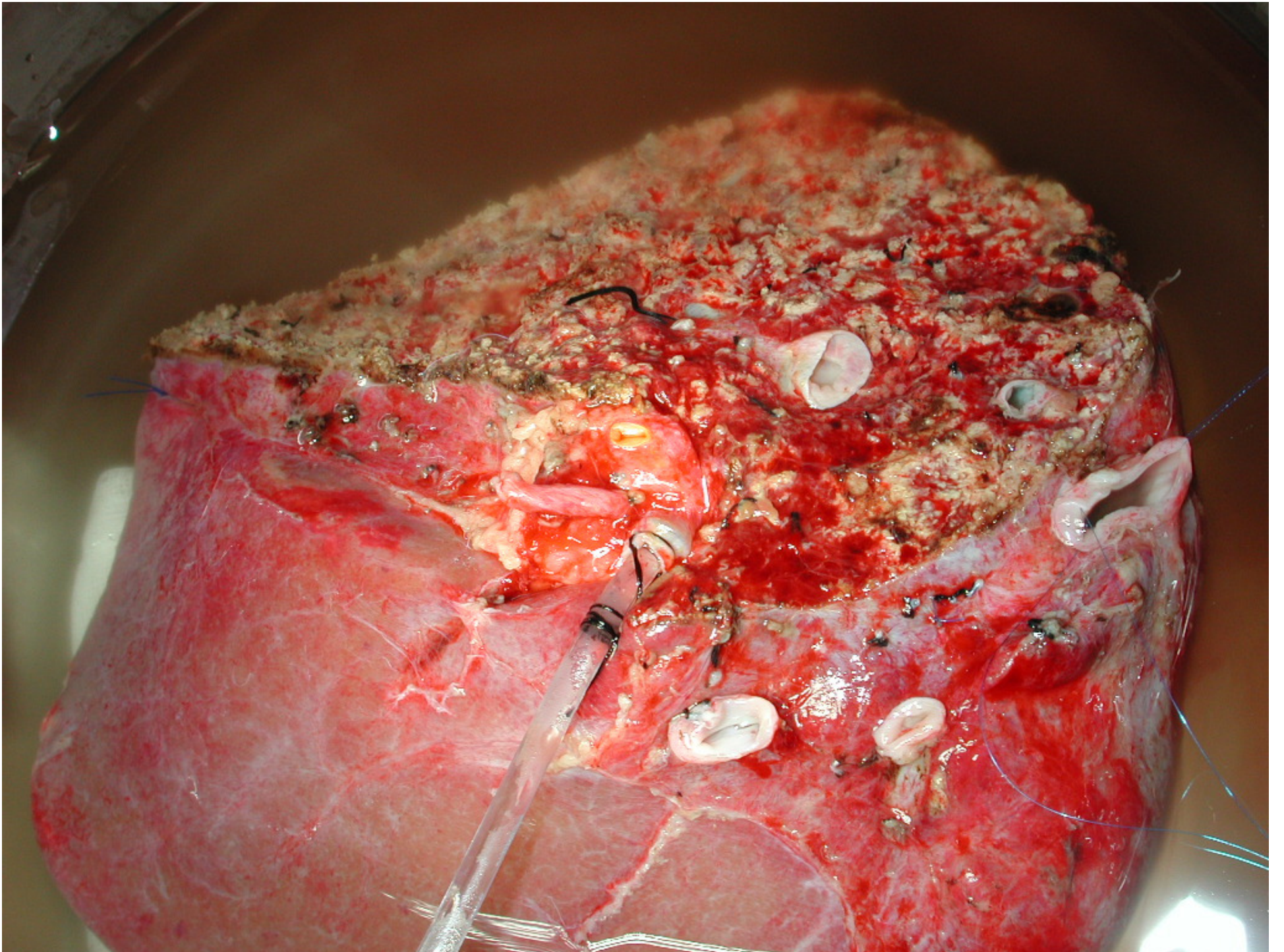


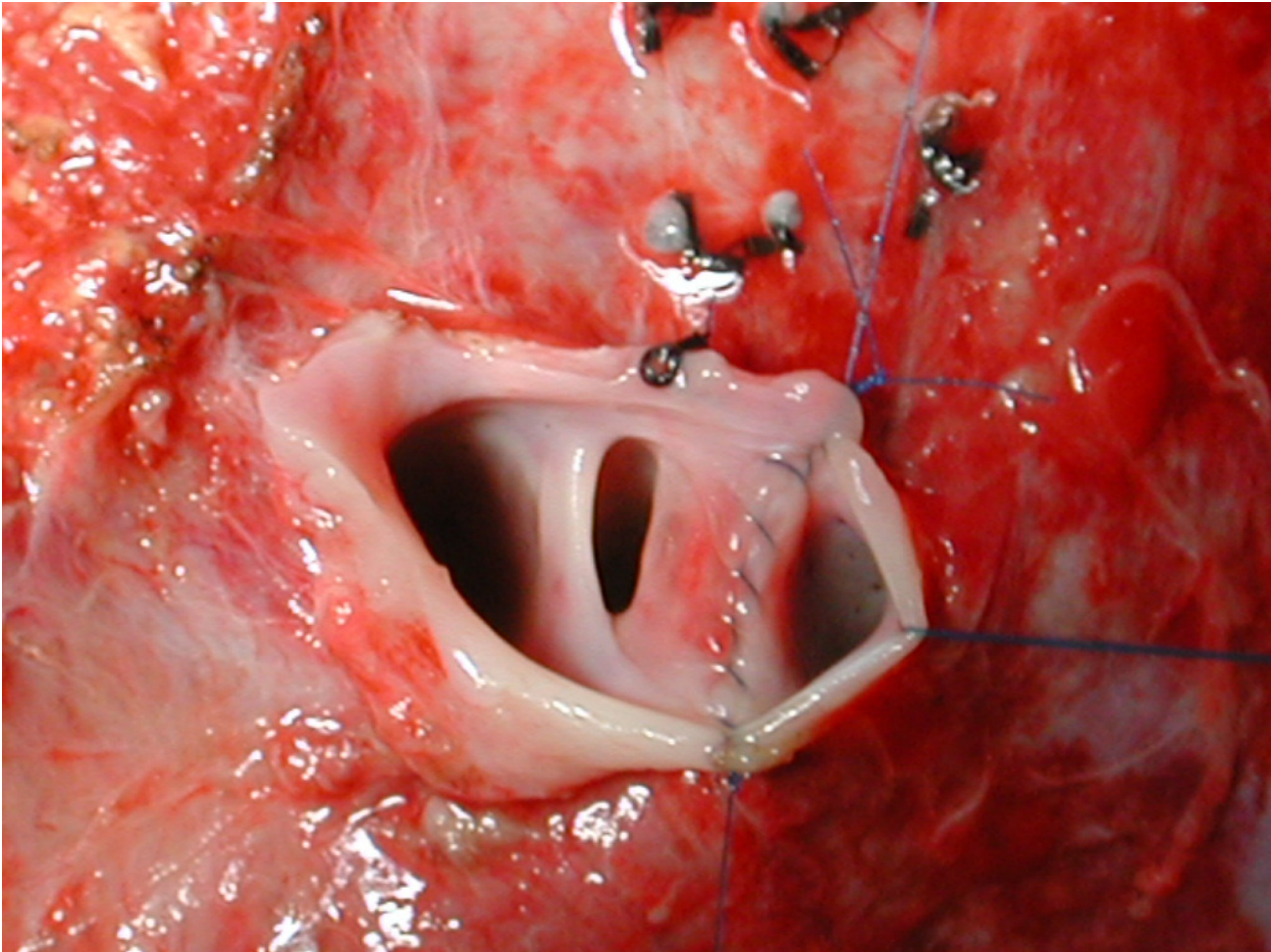


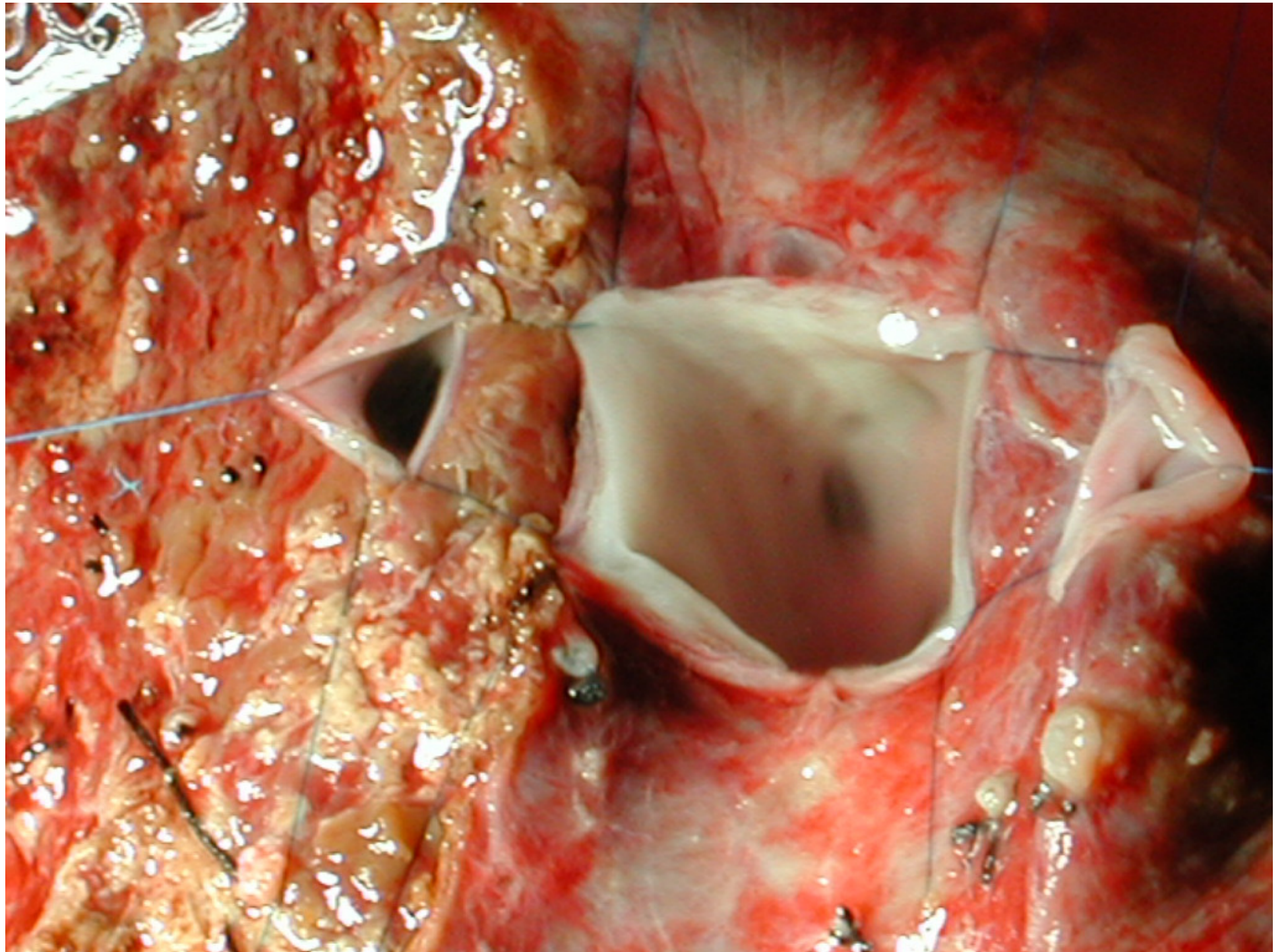
Modificacao Enxerto Lobo D

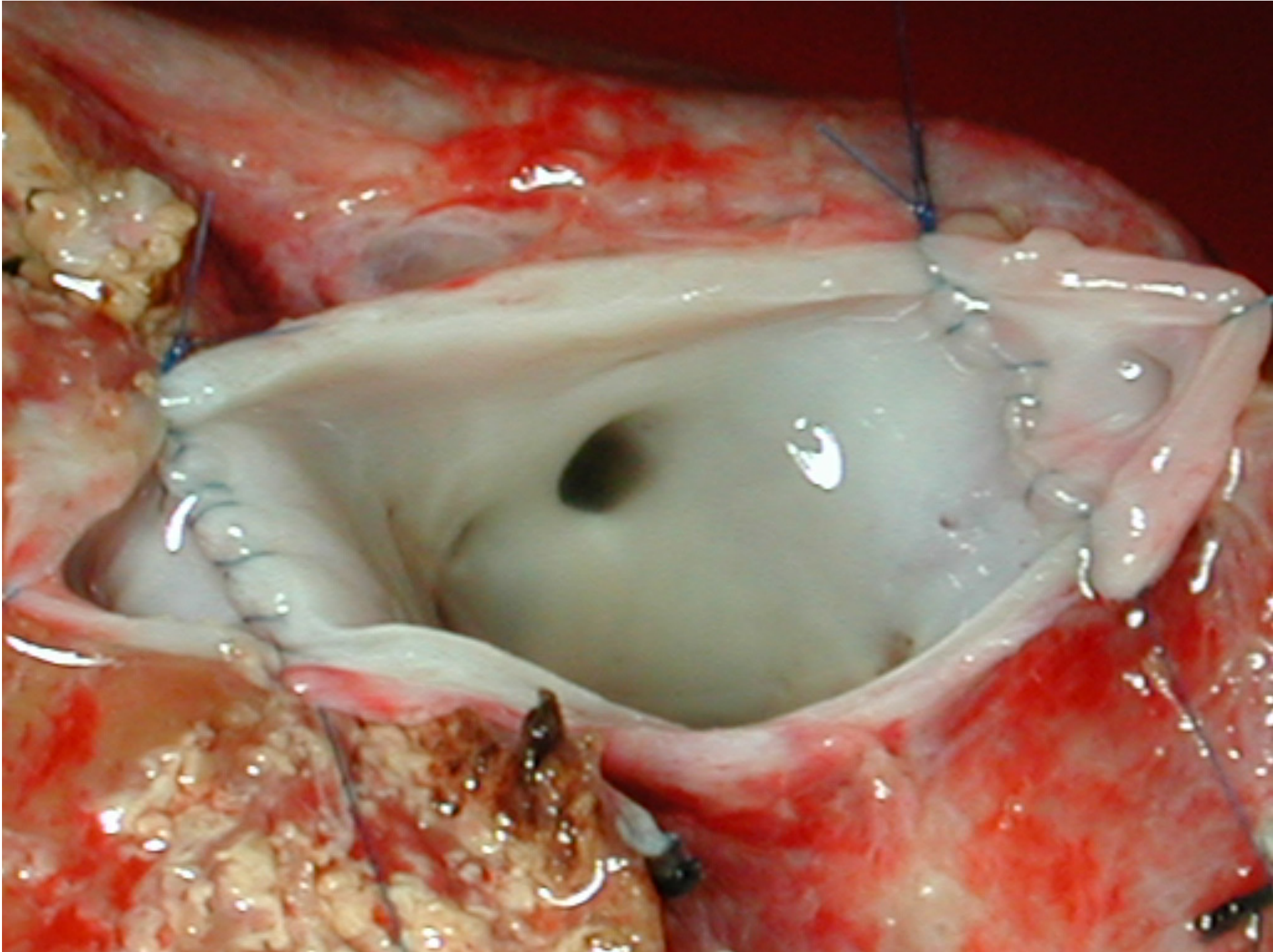


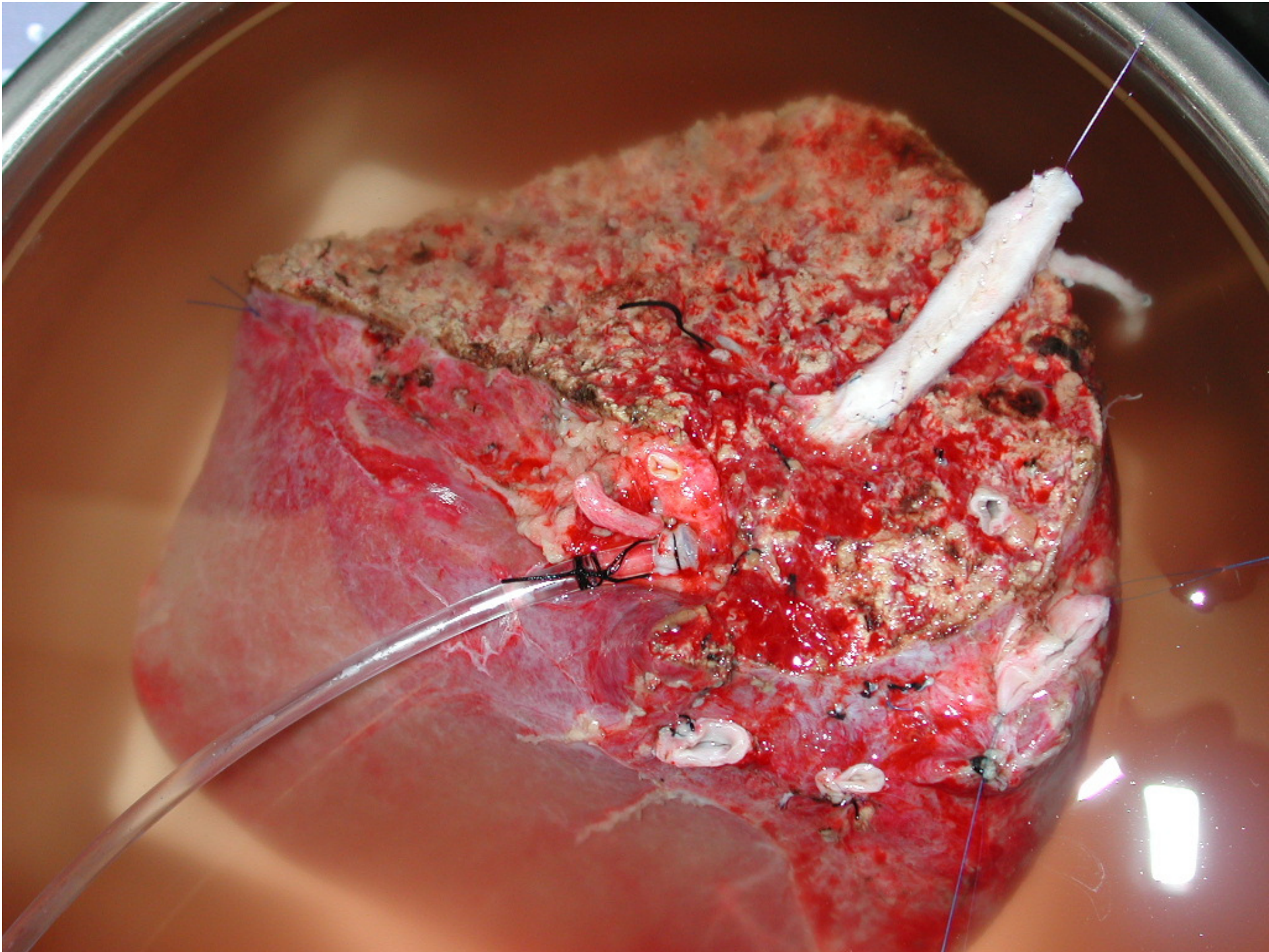
Lee SG et al. Transplantation 2002; 74: 54

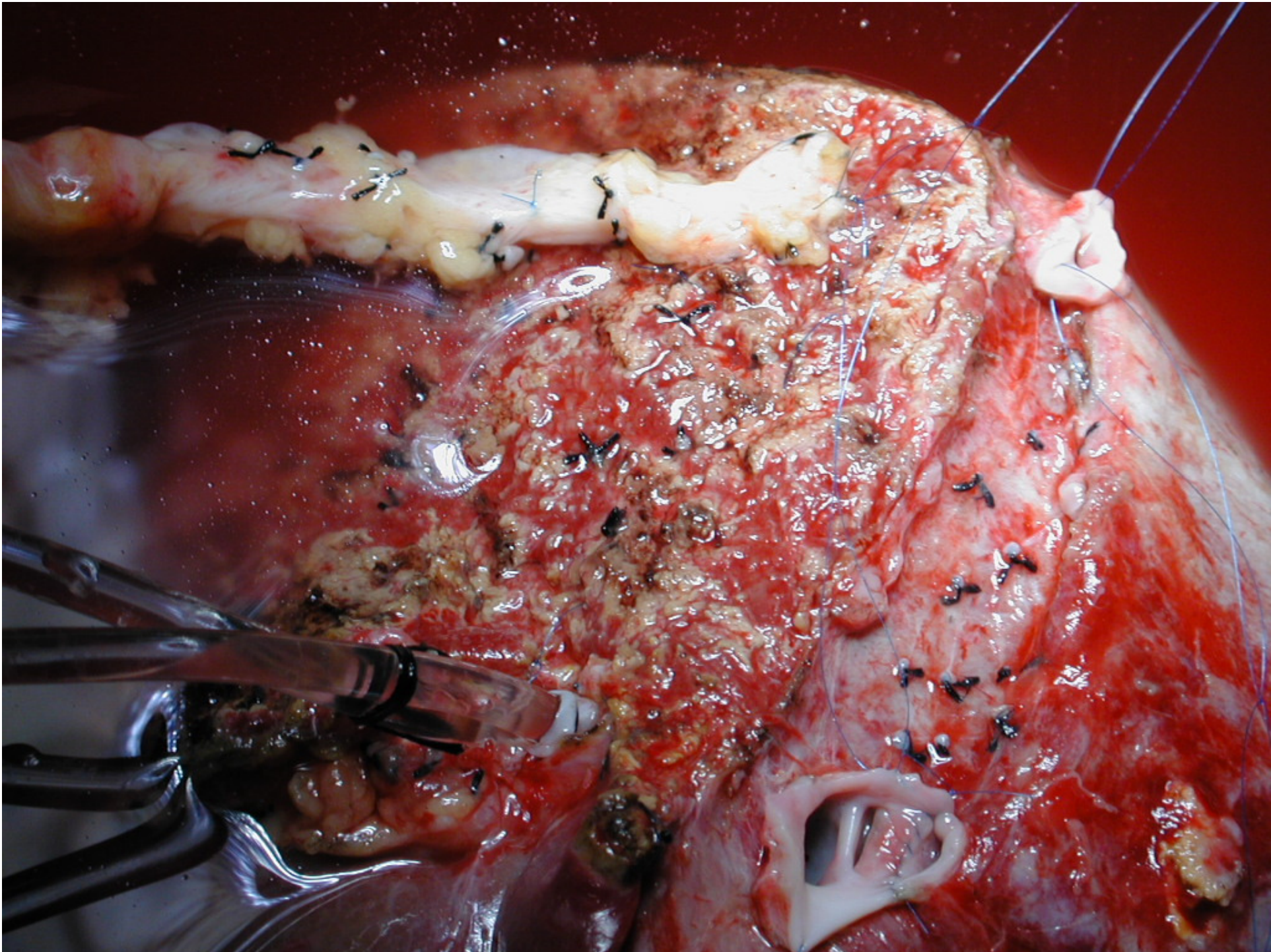


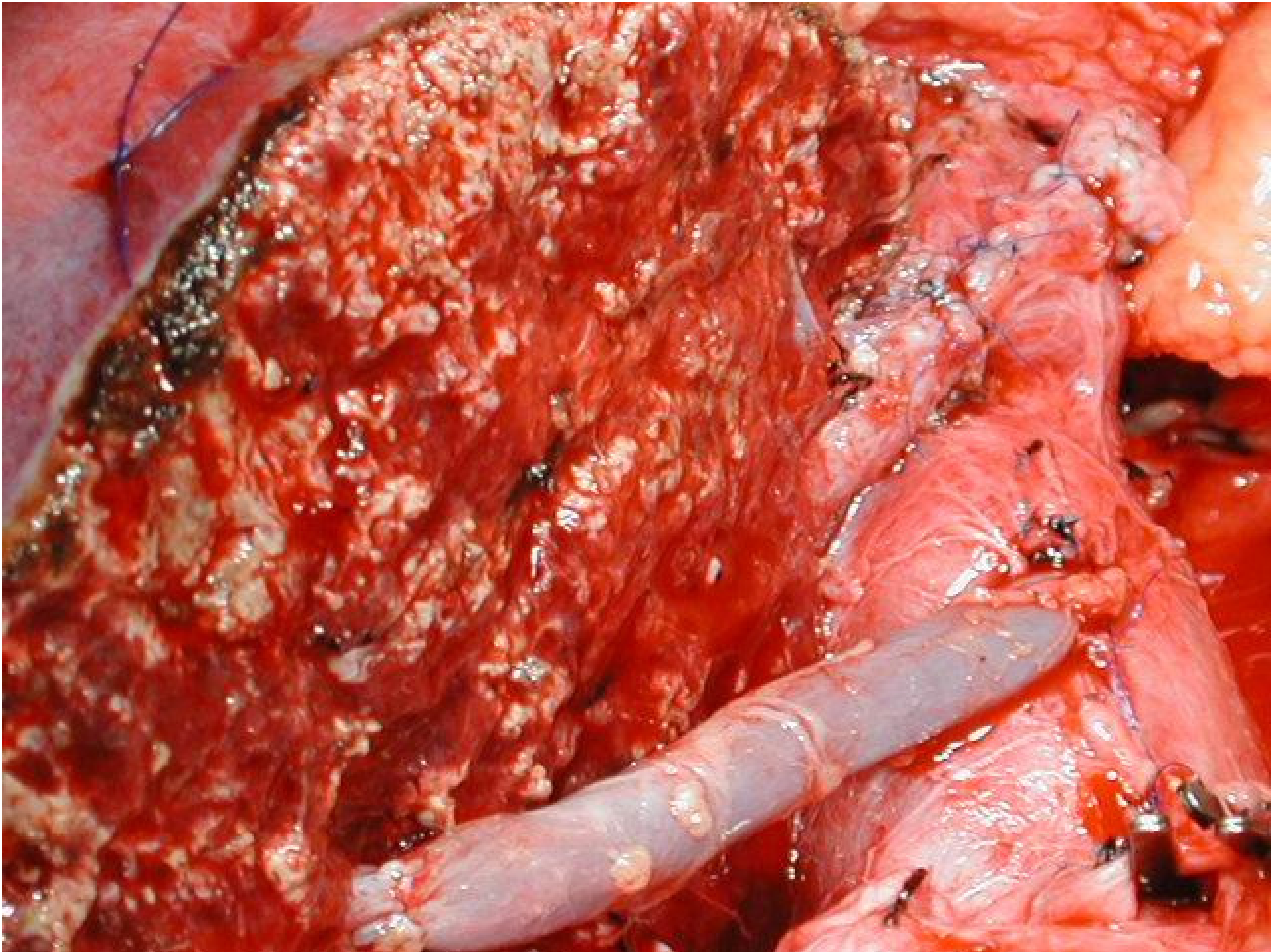

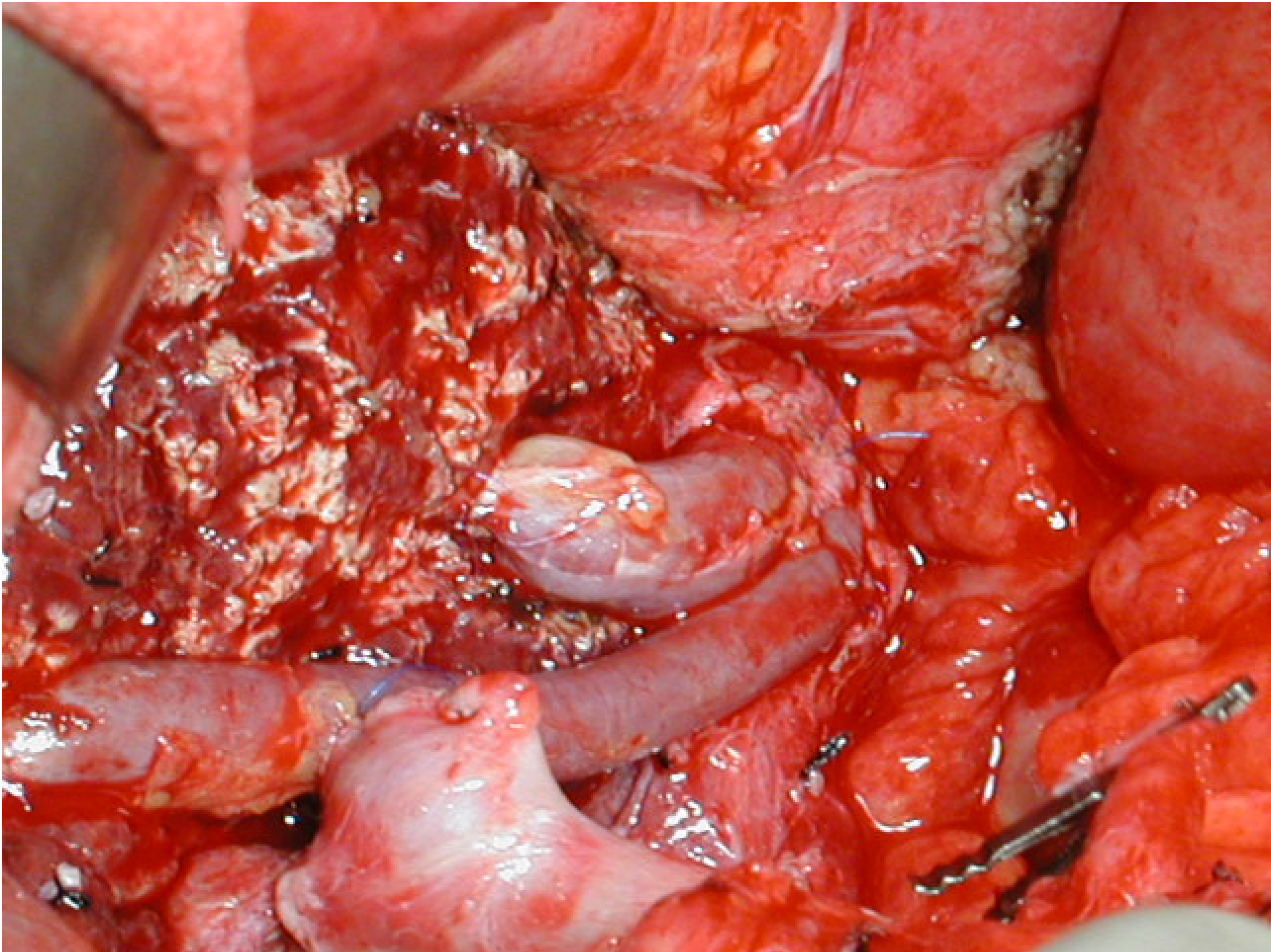


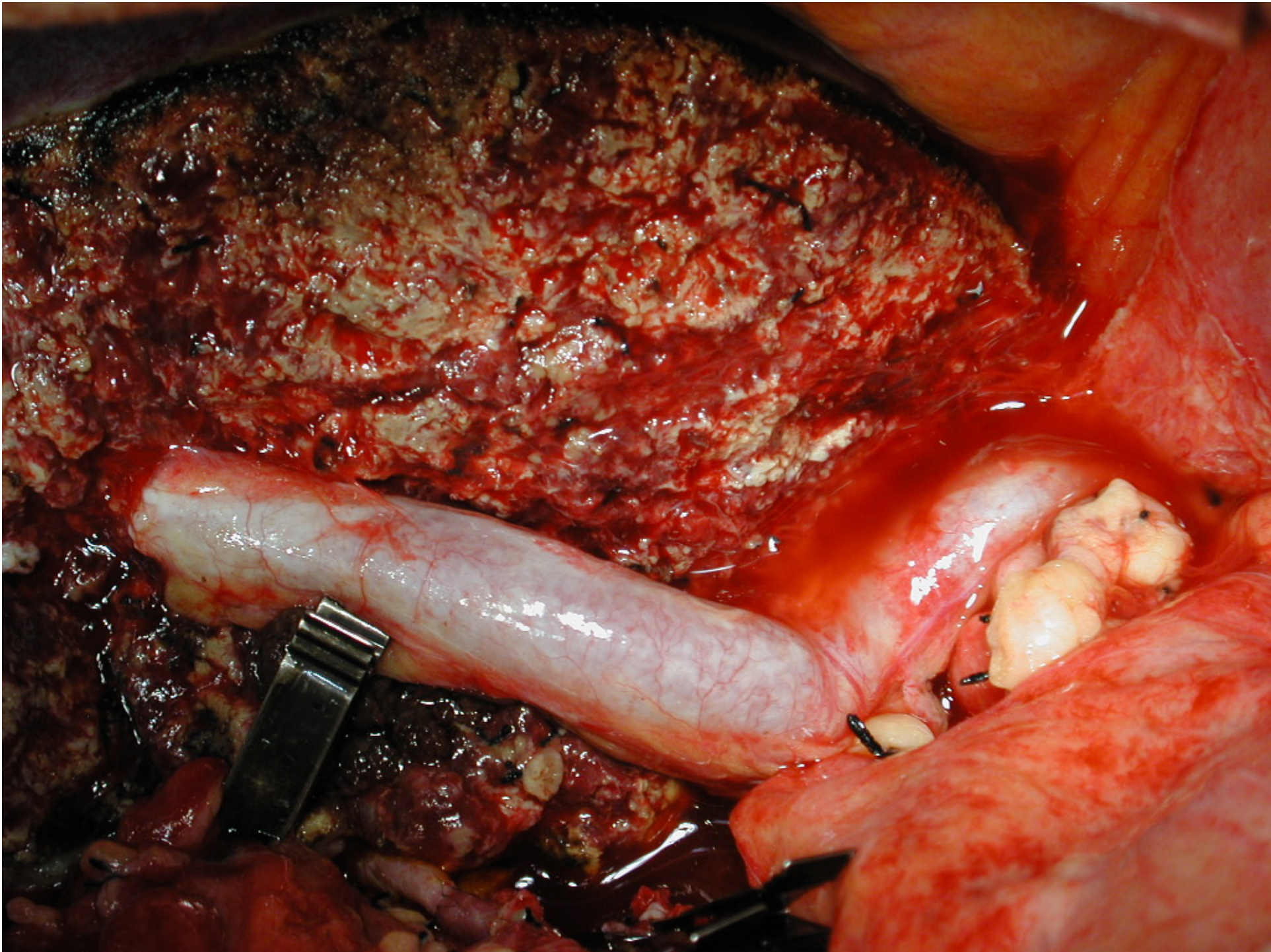


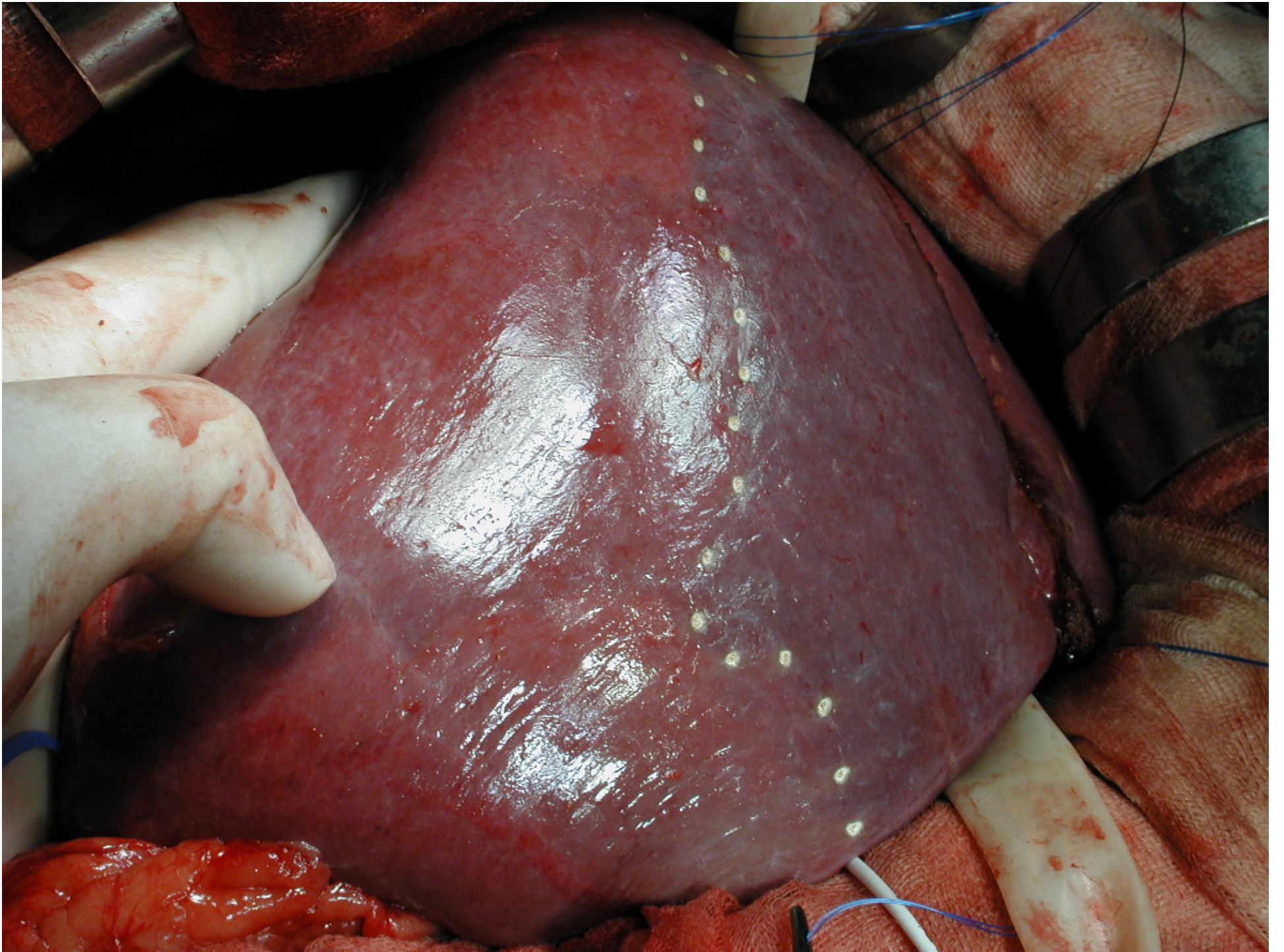


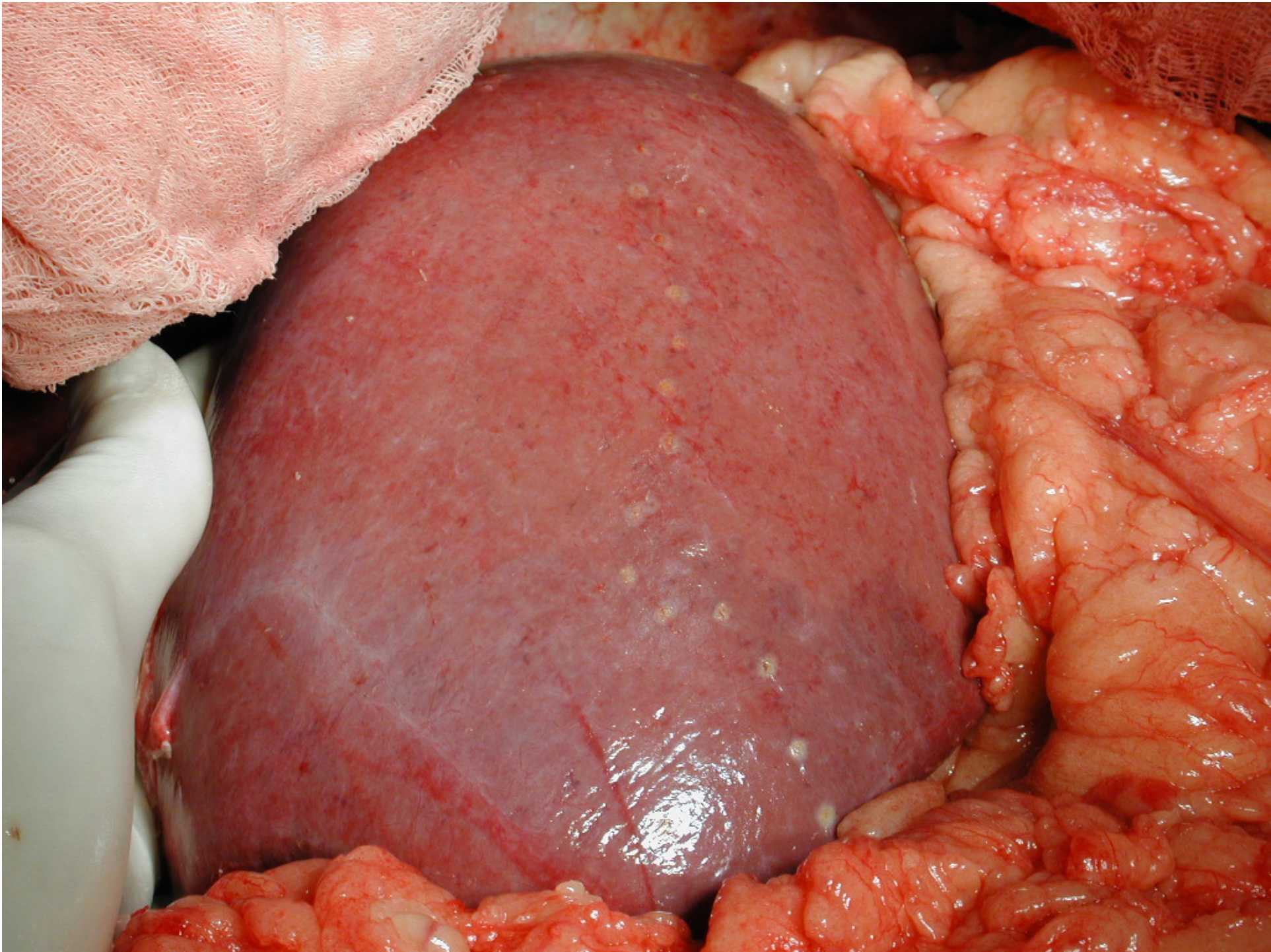


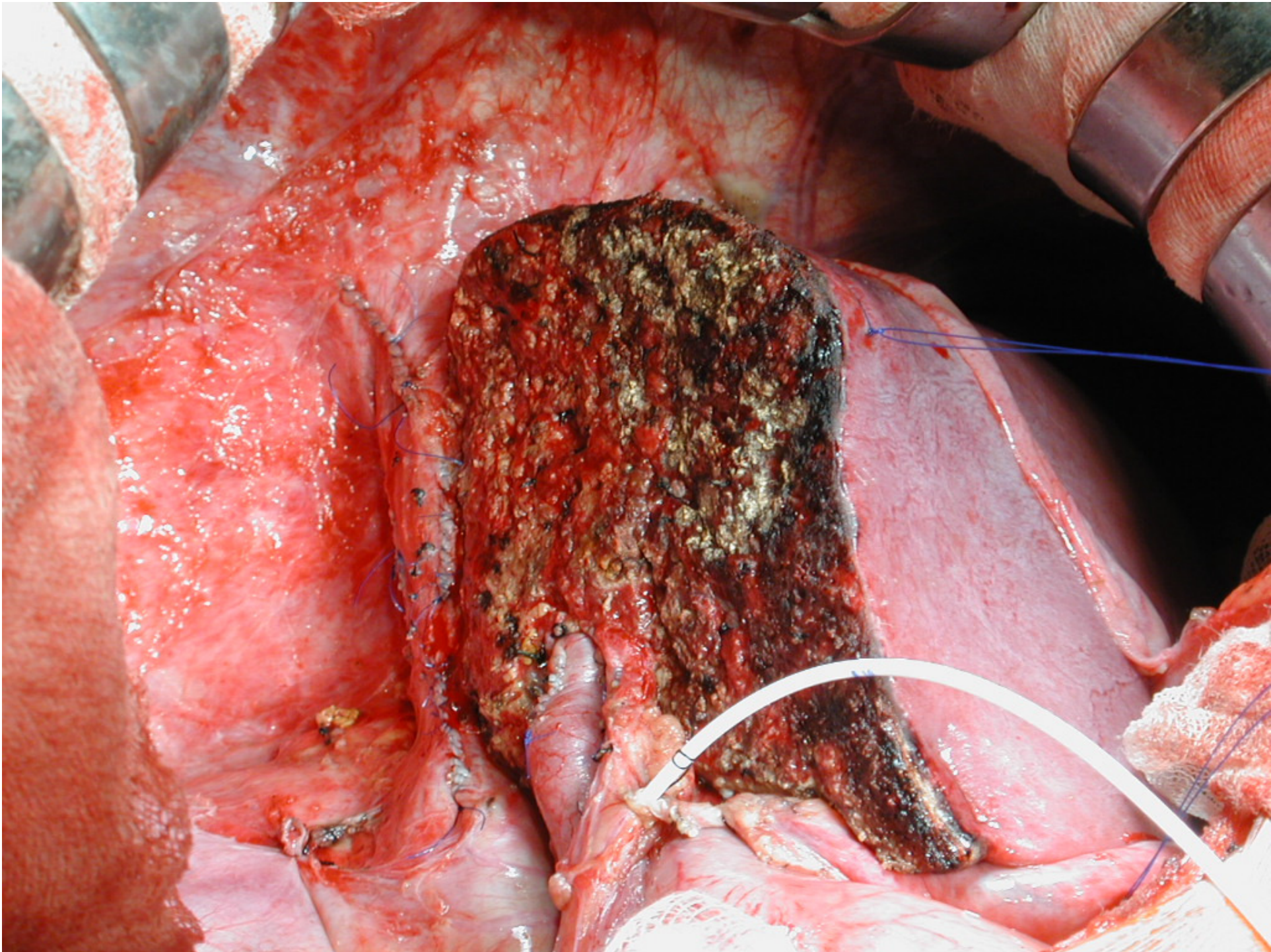


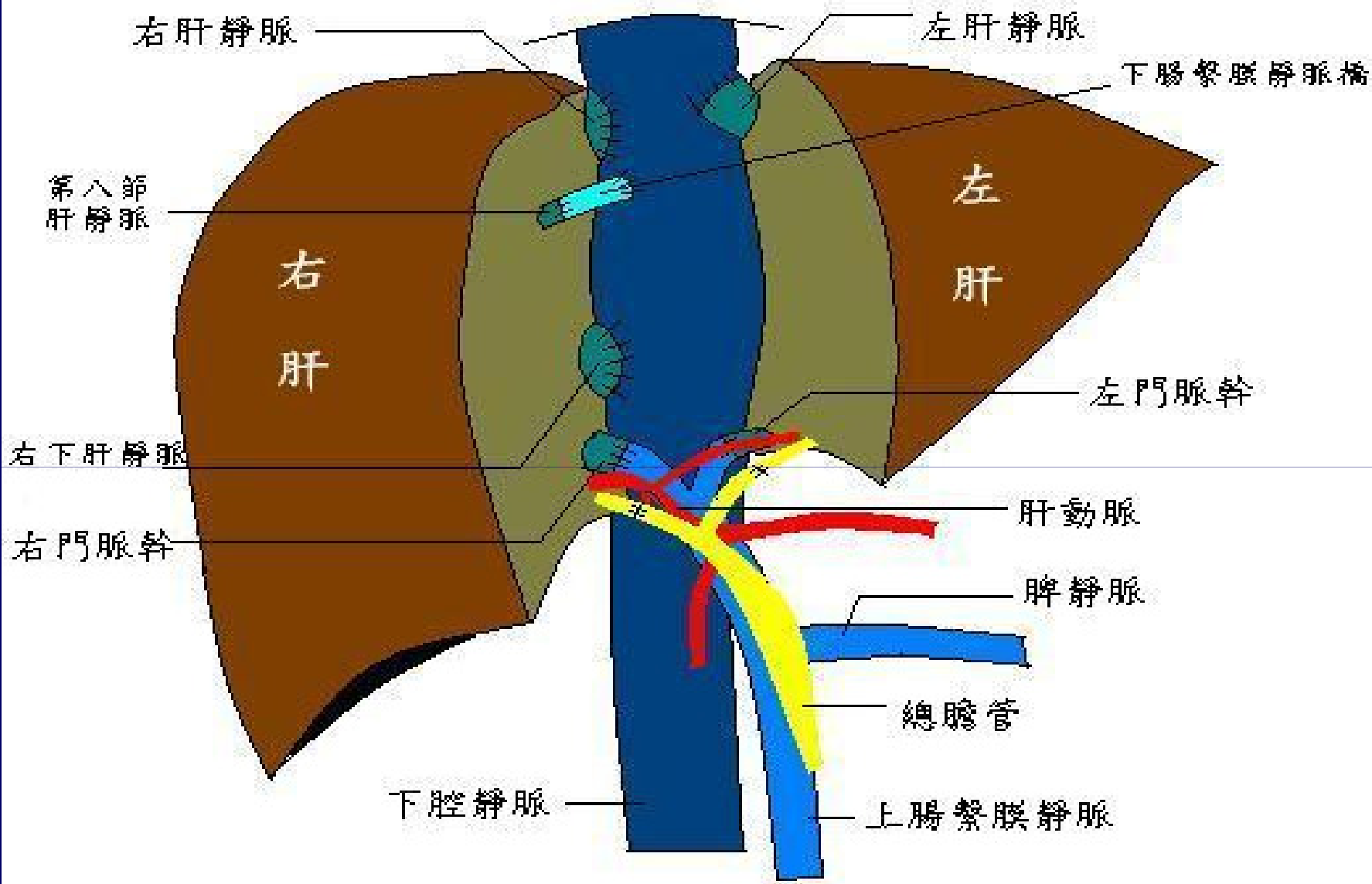


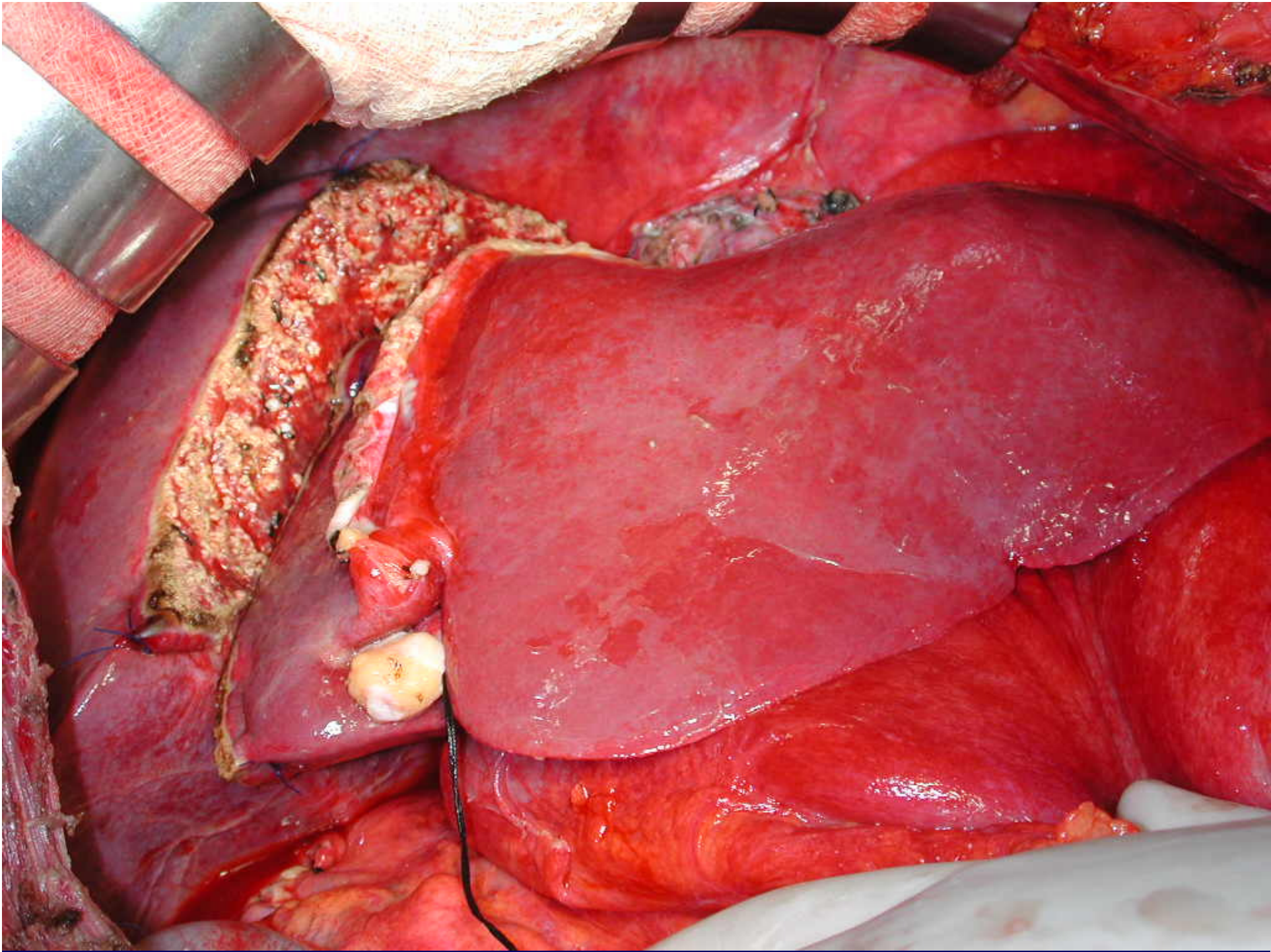



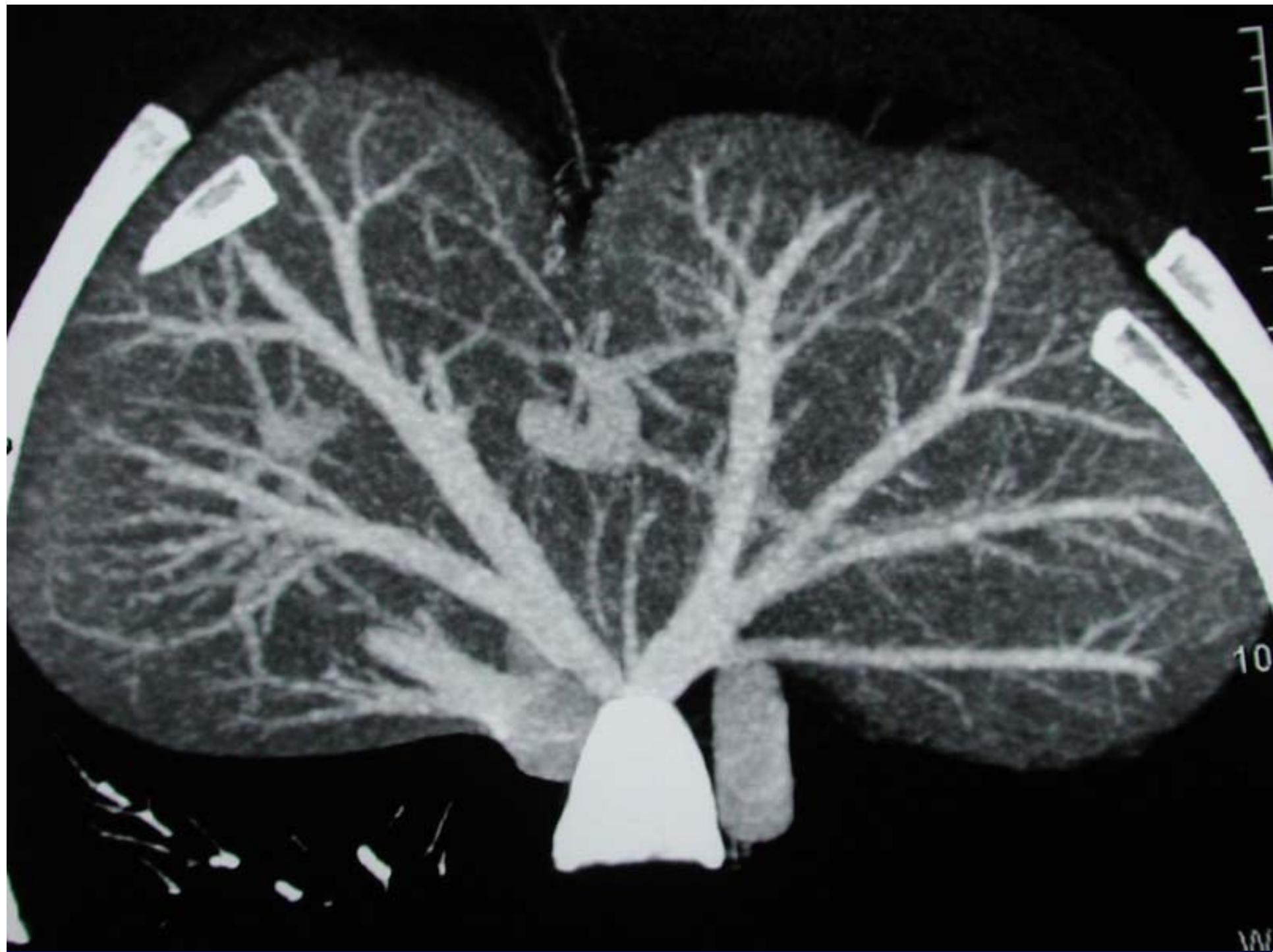


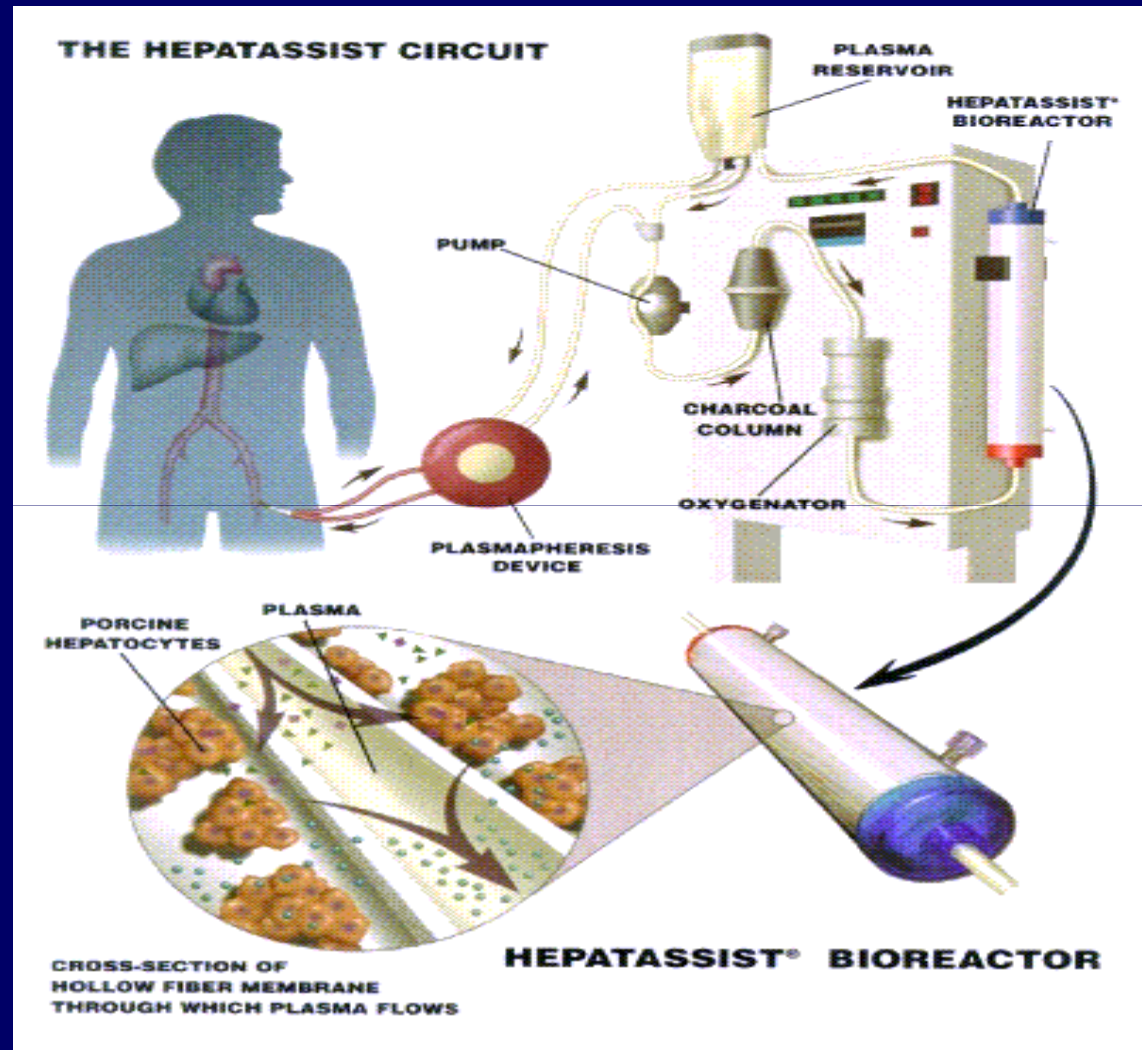


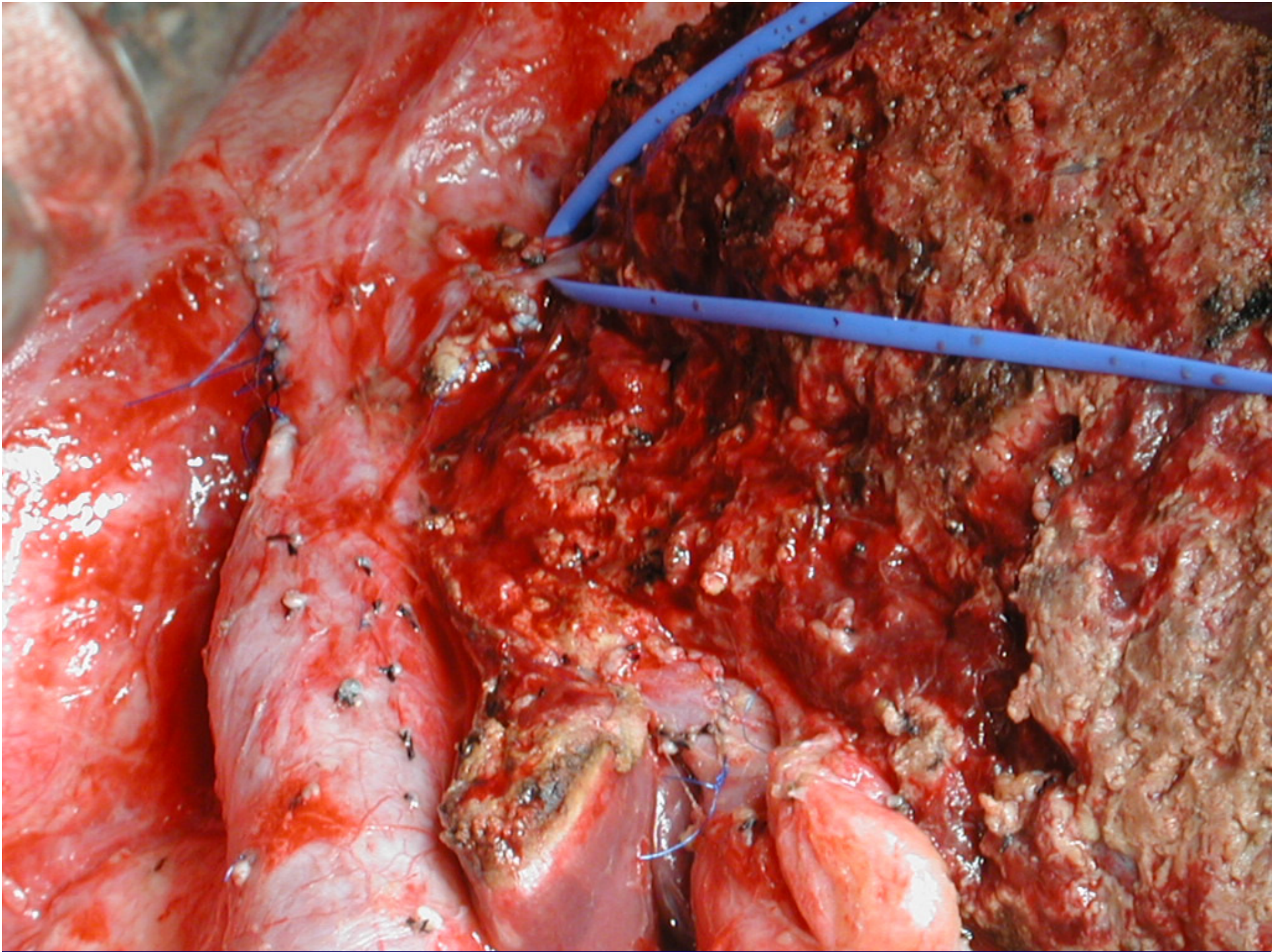




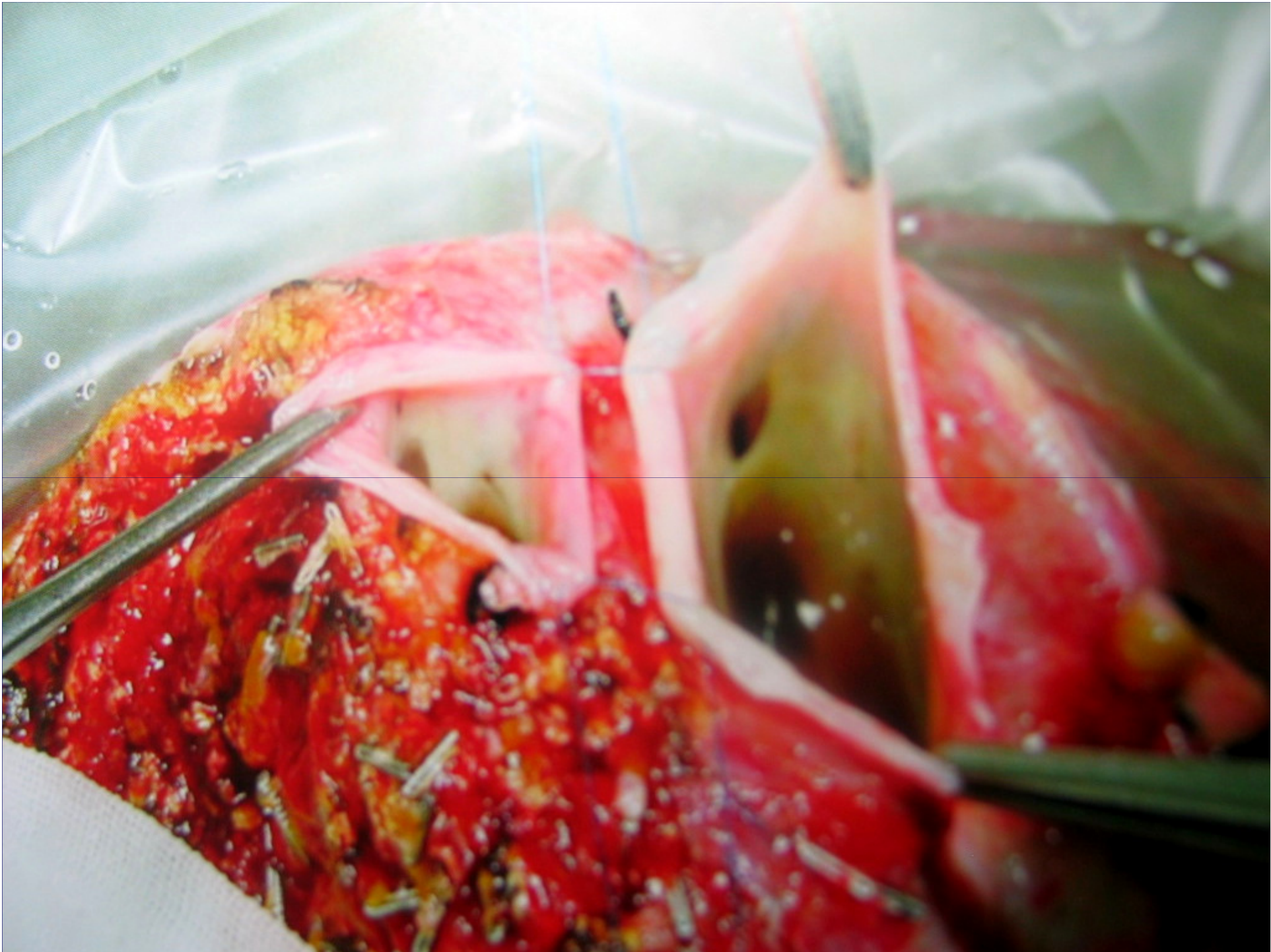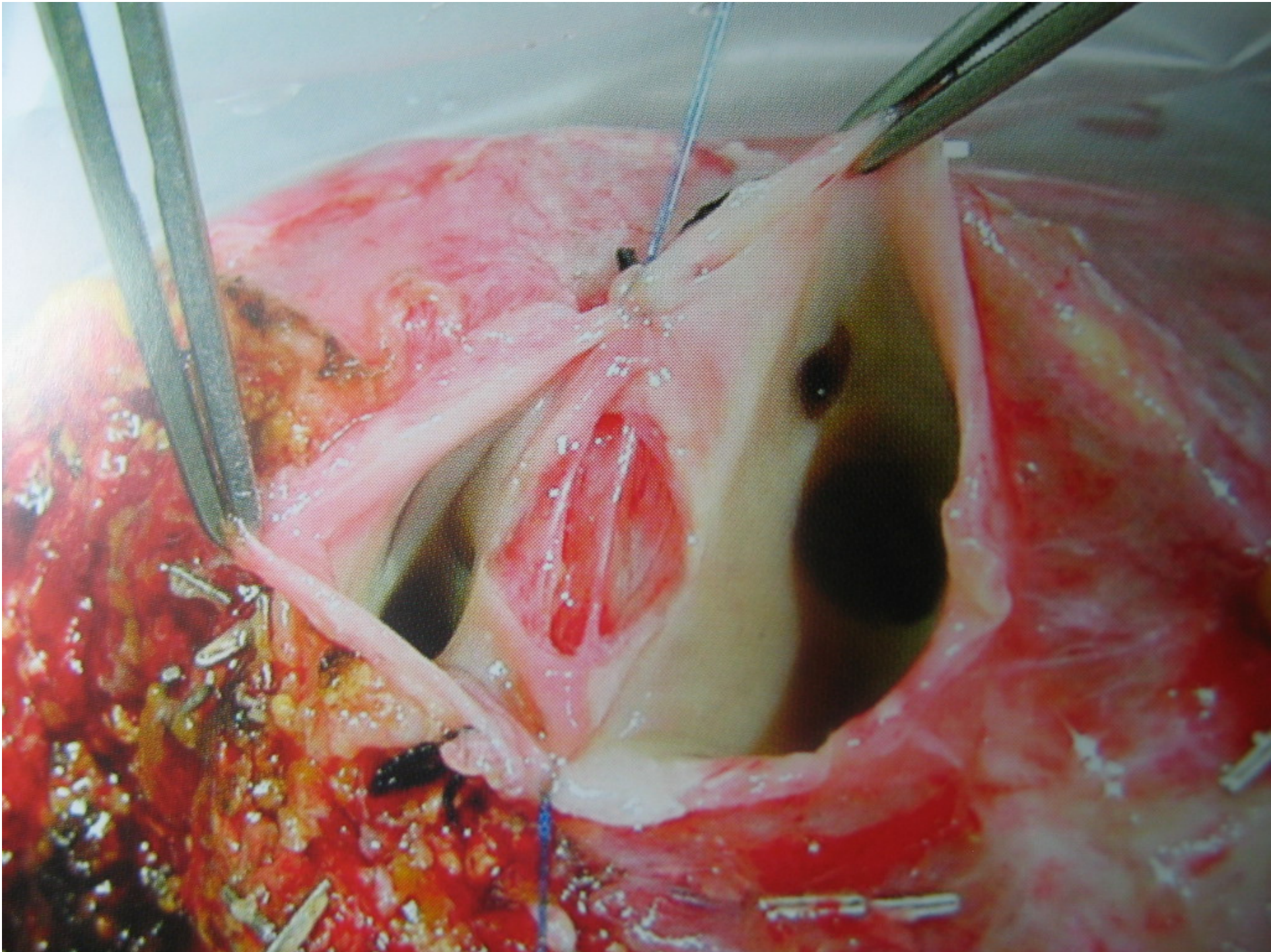


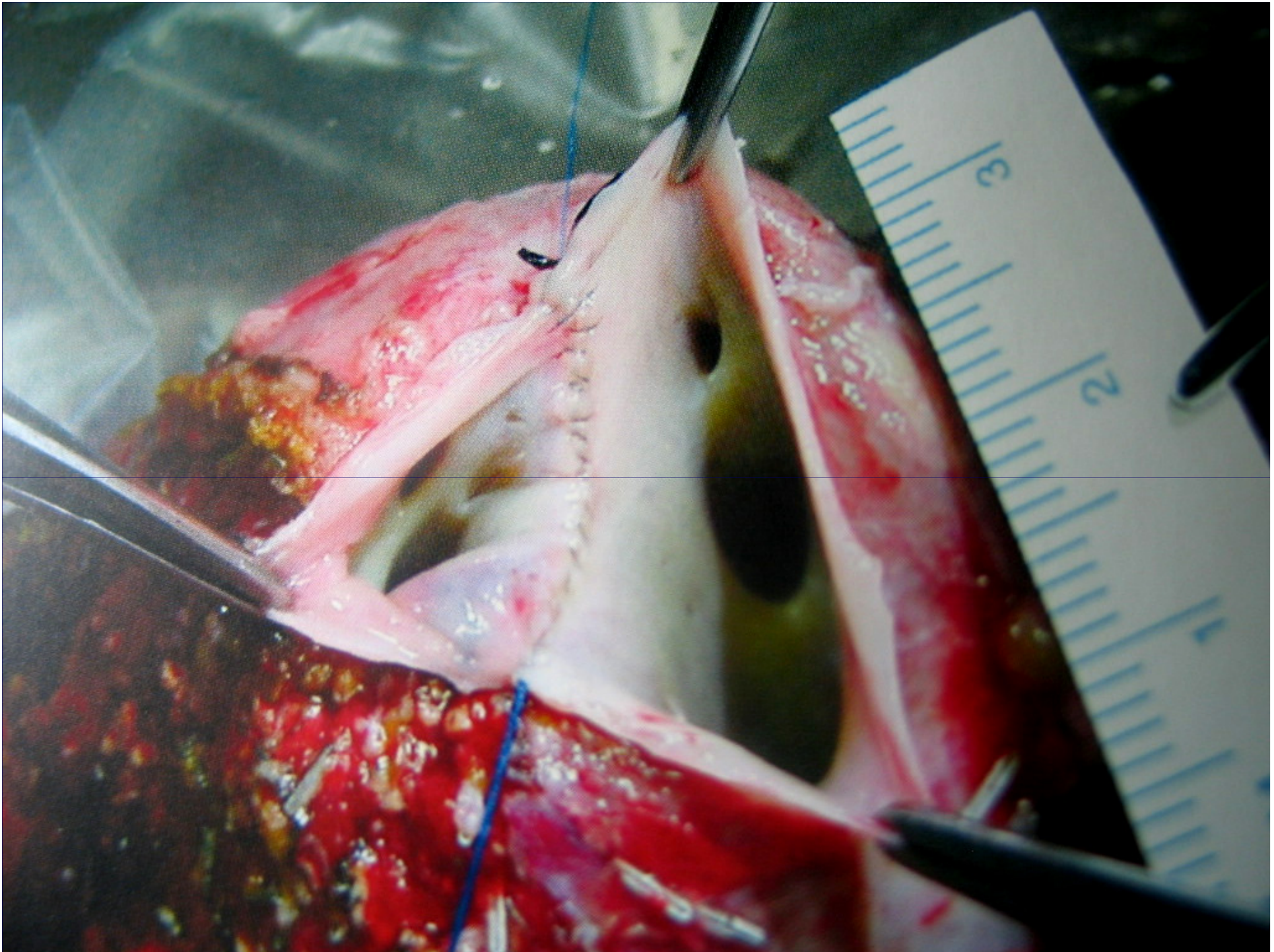
HepatAssist 2000 (Circe Biomedical)

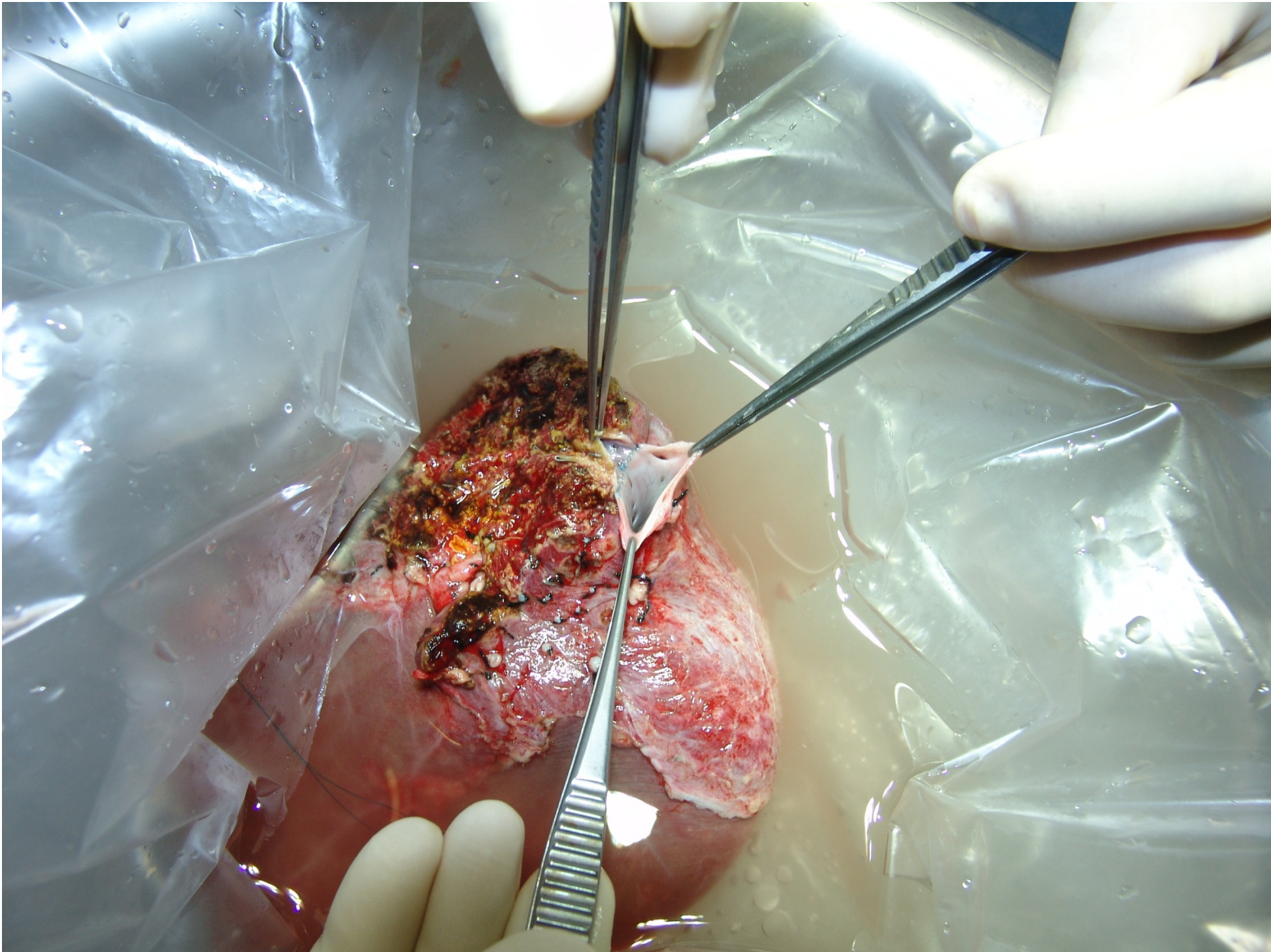


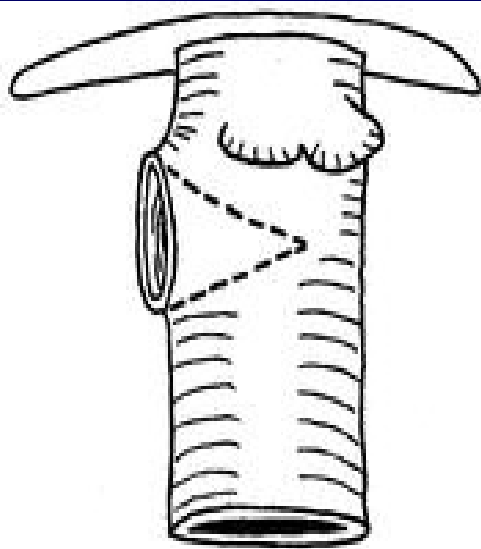




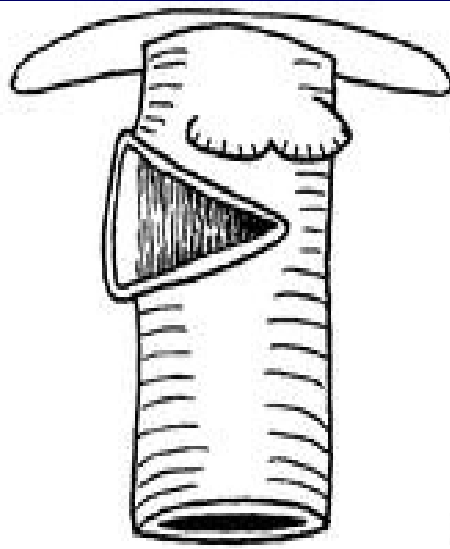




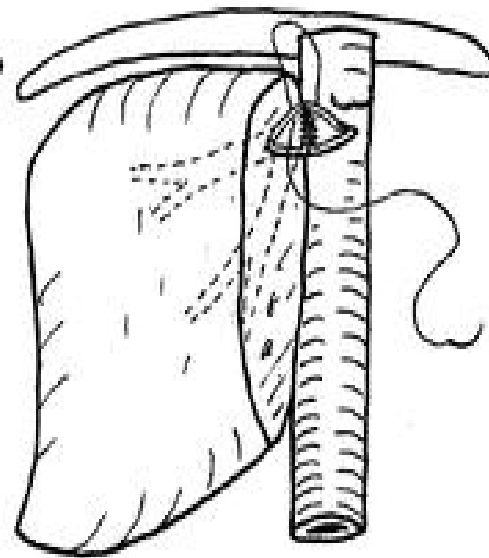




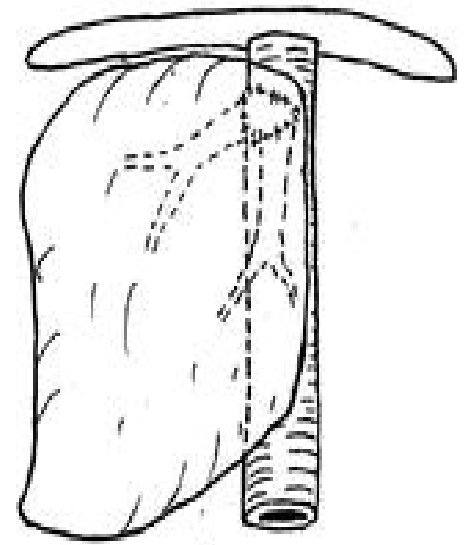
A



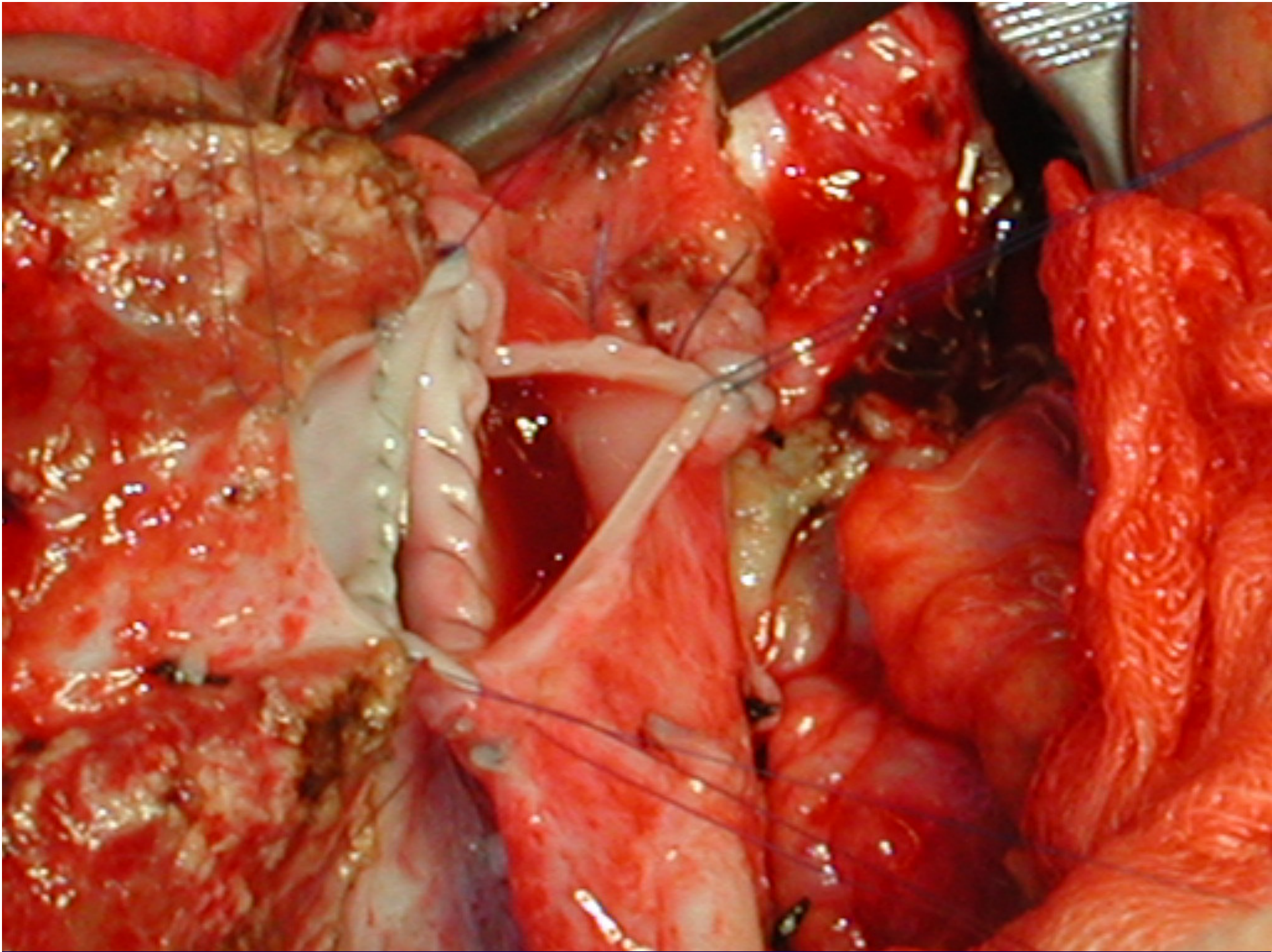
B

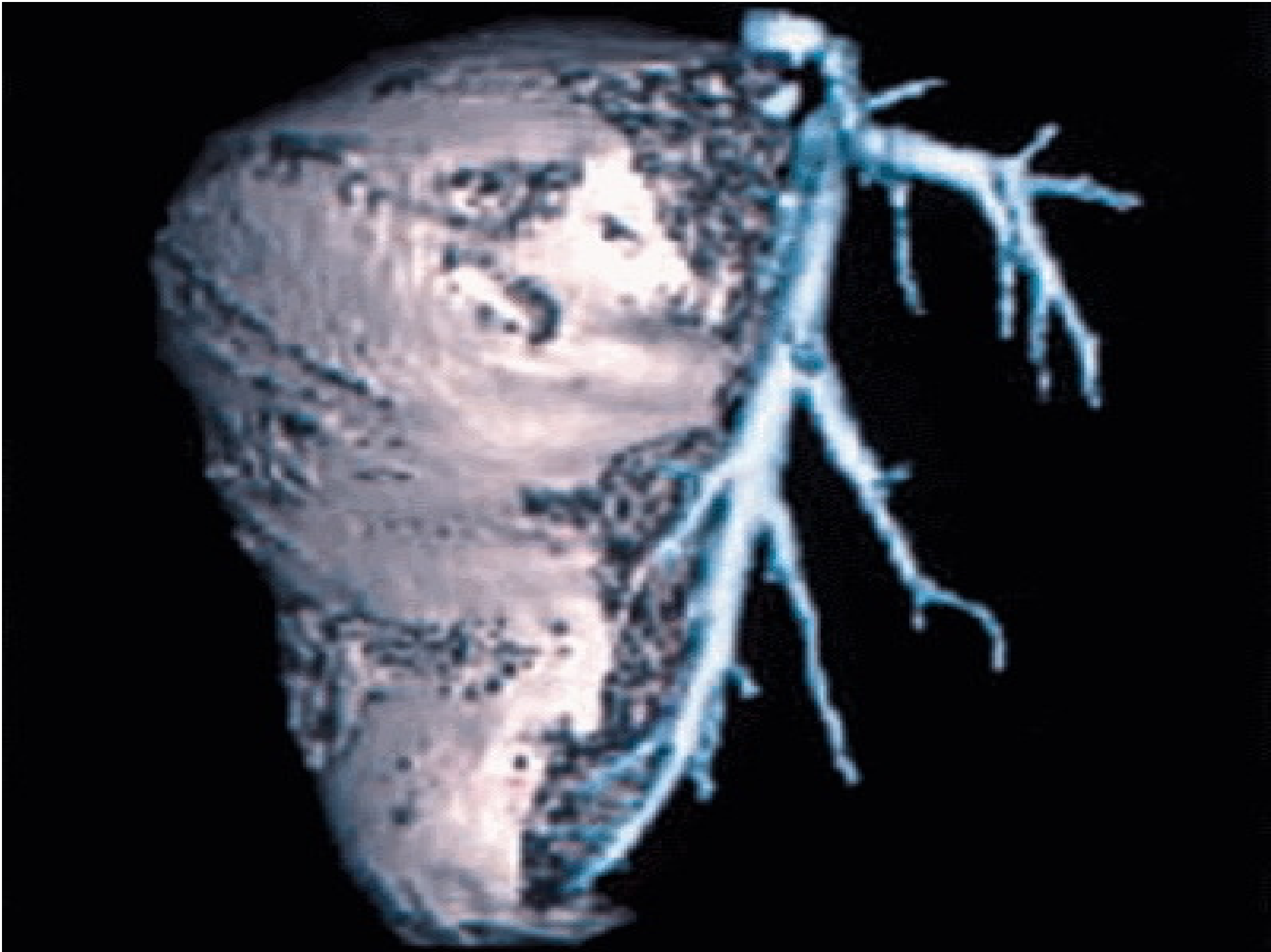


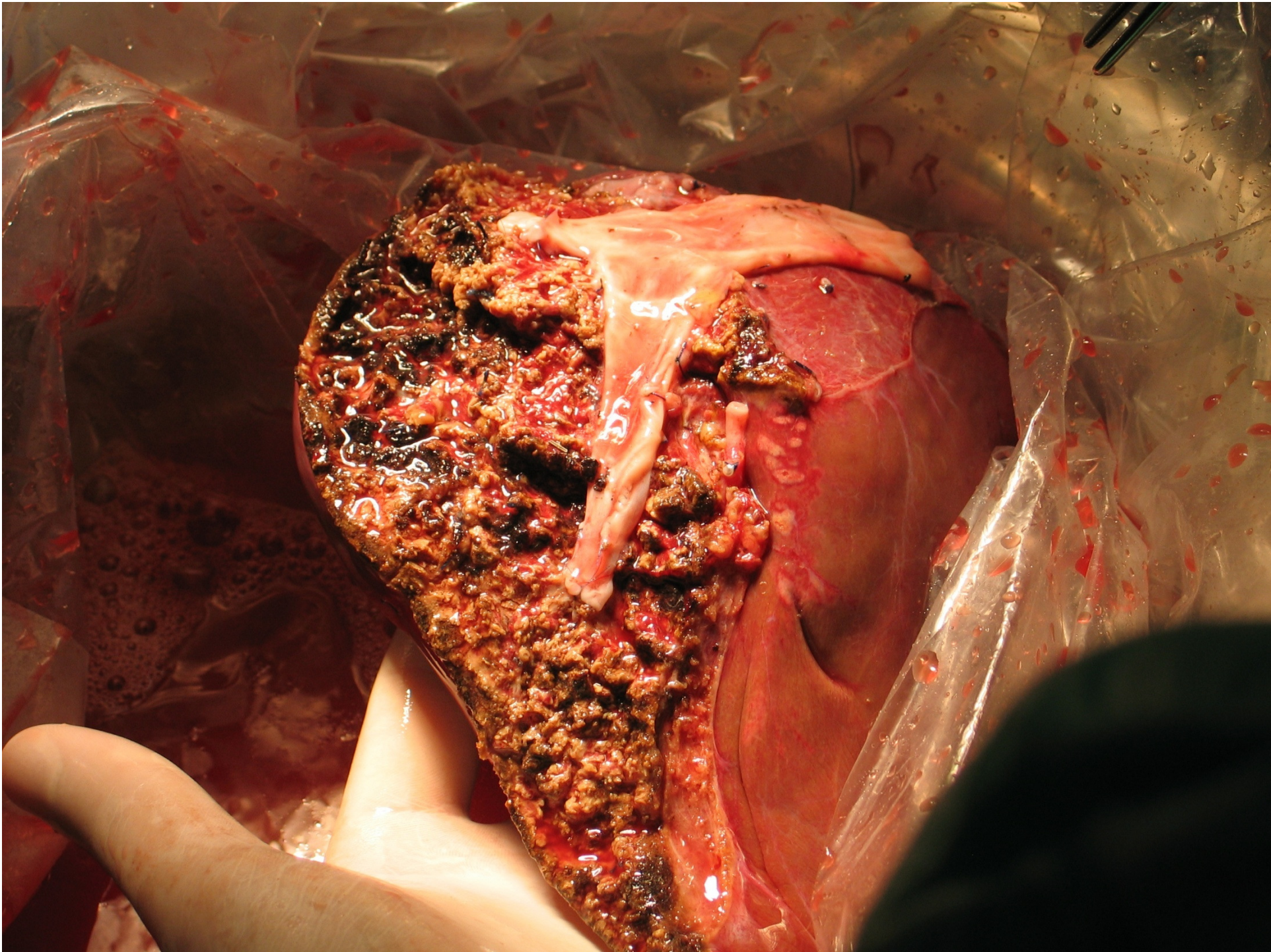C

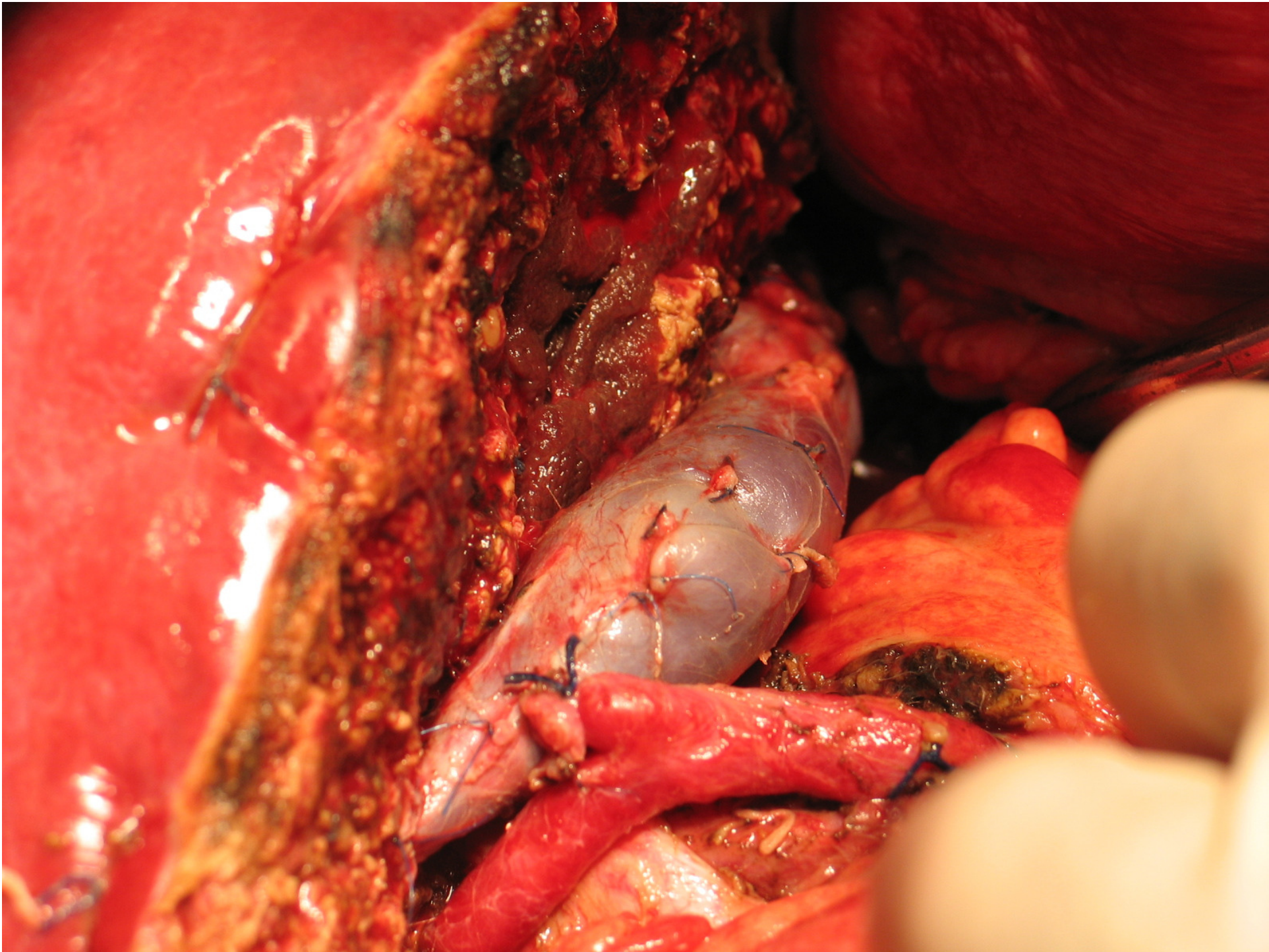


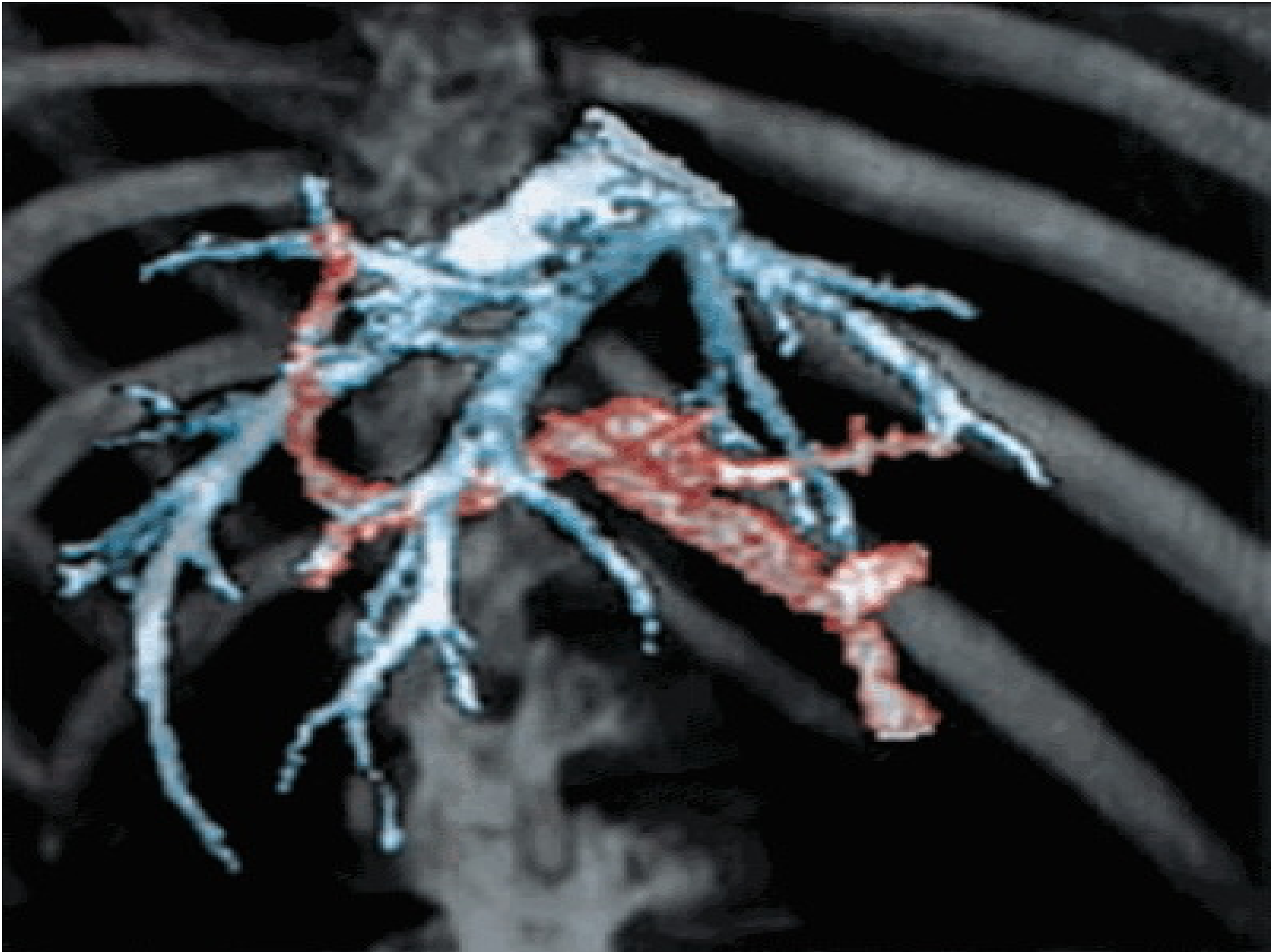
D

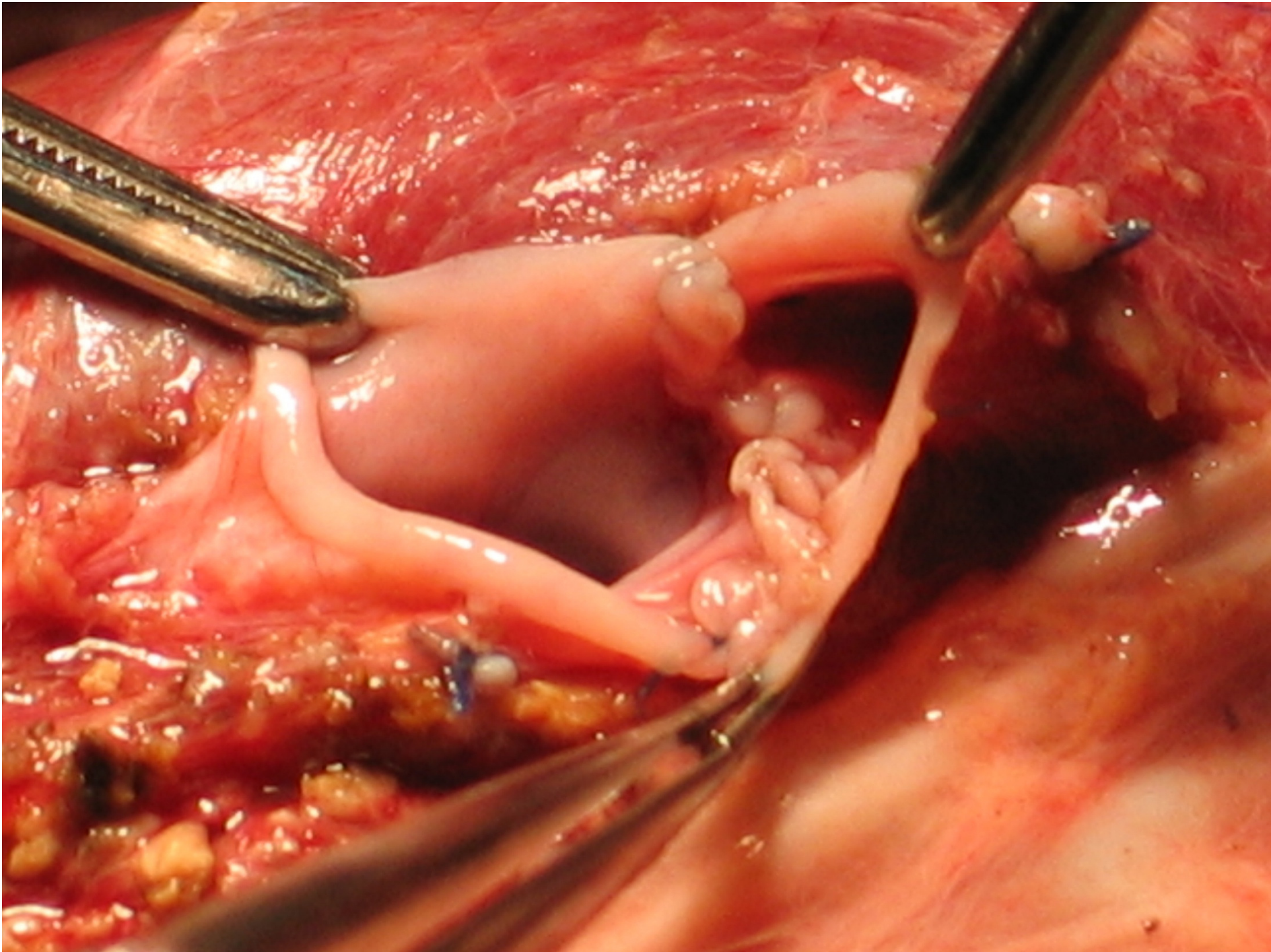














Recomendações

- **Estudo de Imagem detalhado**
- **Técnica cirúrgica meticulosa**
- **PVC baixa**
- **Minima perda sanguínea**
- **transfusão zero**

Chen CL, et al Transplantation 2000; 69: 2580

**“ Não se aprende, Senhor, na Fantasia,
Sonhando, Imaginando ou Estudando,
Senão Vendo , Tratando e Pelejando “**

**Camões, Os Lusíadas
Canto Décimo**